

ACP MESSENGER

Summer 2018

DENTAL PHOTOGRAPHY TIPS

ACHIEVING ESTHETIC SUCCESS

ENGAGEMENT ON SOCIAL MEDIA



ACP
AMERICAN COLLEGE OF
PROSTHODONTISTS

Your smile.
Our specialty.®

INTRODUCING

SpeedCEM® Plus

Self-adhesive resin cement



A BIG PLUS FOR ZIRCONIA

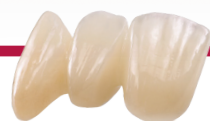THE PLUS FACTORS:

- + **Excellent self-cure performance**
ideal for zirconia and metal-ceramics
- + **User-friendly** handling and easy clean-up
- + **Efficient process** with just one component

RECOMMENDED FOR

IPS e.max® ZirCAD®

The only ZIRCONIA esthetic enough to be called e.max!



ivoclarvivadent.com
EXPLORE SHOP LEARN

For more information, call us at 1-800-533-6825 in the U.S., 1-800-263-8182 in Canada.
© 2018 Ivoclar Vivadent, Inc. Ivoclar Vivadent, IPS e.max, ZirCAD and SpeedCEM are registered trademarks of Ivoclar Vivadent, Inc.

**ivoclar
vivadent®**
passion vision innovation

In This Issue

Summer 2018 Volume 49 Issue 3

6 Same planet, different worlds

Miles R. Cone, DMD, MS, CDT, FACP

Prosthodontists view the human dentition through an entirely different lens than patients – or anyone else in dentistry.

8 Dental photography: the flash war

Luiz H. Gonzaga, DDS, MS

The art and science behind various aspects of dental photography and how to communicate with both the patient and the rest of the treatment team.

12 What happens when the implant fails

Armand Bedrossian, DDS

The role that hard and soft tissue integration plays in complex treatment planning and the predictability and reality of dental implants for full-mouth rehabilitations.

16 Have you lost faith in Facebook?

Margie Arnett, MS

Social media marketing strategies to connect with prospective patients.

18 Choose to be the bus driver

Robert M. Taft, DDS, FACP, ACP President

Prosthodontists drive innovation in dentistry. How do we bring others on board?

20 Has there ever been a better time to be a prosthodontist?

Leonard B. Kobren, DDS, ACPEF Chair

Celebrating recent successes and the importance of self-investment.

22 Annual Session News

26 National Prosthodontics Awareness Week Highlights

31 Our Community

32 Upcoming Events

35 Classified Ads



AMERICAN COLLEGE OF
PROSTHODONTISTS
Your smile. Our specialty.®

Editor-in-Chief

Miles R. Cone, DMD, MS, CDT, FACP

Associate Editors

Nadim Z. Baba, DMD, MSD, FACP

Stephen I. Hudis, DDS, FACP

Consulting Editor

Susan E. Brackett, DDS, MS, FACP

Editor Emeritus

Lyndon F. Cooper, DDS, PhD, FACP

ACP Board of Directors

Robert M. Taft, DDS, FACP, President

Nadim Z. Baba, DMD, MSD, FACP, President-Elect

Stephen I. Hudis, DDS, FACP, Vice President

Daniel A. Givan, DMD, PhD, FACP, Secretary

Mark C. Hutten, DDS, MS, FACP, Treasurer

Susan E. Brackett, DDS, MS, FACP, Immediate Past President

Elphida G. Ayvazian, DMD, Director, Public Relations & Communications Division

John D. Ball, DDS, FACP, Regional Membership Director – Central

Douglas G. Benting, DDS, MS, FACP, Director, Prosthodontic Forum

Lars Bouma, DDS, MS, FACP, Director, Continuing & Professional Education Division

Linda Caradine-Poinsett, MBA, MJ, PhD, Executive Director

Lyndon F. Cooper, DDS, PhD, FACP, Chair, ACP Education Foundation

Thomas B. Girvan, DMD, FACP, Regional Membership Director – Federal Services

Gerald T. Grant, BA, DMD, MS, FACP, Director, Maxillofacial Prosthetics Division

Radi M. Masri, DDS, MS, PhD, FACP, Editor-in-Chief, *Journal of Prosthodontics*

Steven M. Morgana, DMD, FACP, Regional Membership Director – Northeast

Caroline T. Nguyen, DMD, MS, FACP, Regional Membership Director – International

B. Todd Pickle, DDS, MSD, FACP, Regional Membership Director – Rockies/Plains

Paivi A. Samant, DDS, Regional Membership Director – Eastern

Robert E. Stover, DDS, MS, FACP, Regional Membership Director – Pacific

Stephen A. Wagner, DDS, FACP, Director, Prosthodontic Practice & Patient Care Division

Alvin G. Wee, DDS, MS, MPH, PhD, Director, Education & Research Division

ACP Central Office Staff

Linda Caradine-Poinsett, MBA, MJ, PhD, Executive Director

Mark Heiden, MS, Associate Executive Director, Communications & Marketing

Melissa Kabadian, MA, CMP, Associate Executive Director, Education & Meetings

Alethea Gerding, MA, Managing Editor, *Journal of Prosthodontics*

Jenny Lara, Administrative Assistant

Justin McDaniel, Membership Services Manager

Olivia Moukayed, Education & Meetings Manager

Adam Reshan, Director, Membership Services & Academic Relations

Evan Summers, Public Relations Specialist

Lauren Swanson, Communications & Marketing Manager

Carrie Villa, MM, Director, Finance & Administration

Nathalie Williams, Director, Sections & Governance

Managing Editor

Lauren Swanson

Advising Editor

Mark Heiden

Design

Publications Associates, Inc.

Display Advertising

Stephanie Kogel, M.J. Mrvica Associates, Inc.

Phone: (856) 768-9360 Email: skogel@mrsvica.com

Classified Advertising

Visit Prosthodontics.org to download an insertion form. Email or fax the completed form to Lauren Swanson at lswanson@prosthodontics.org or (312) 573-1257. Classified ads are \$150 for the first 50 words and \$1 for each additional word for ACP members. The non-member rate is \$250 for the first 50 words and \$2 for each additional word. The minimum charge is \$150. Logos are an additional \$50, limited to one per ad and subject to approval. Payment by check, American Express, Visa, or Mastercard is required prior to placement.

The mission of the ACP Messenger is to inform readers about current prosthodontic trends, challenges, and successes. Statements of fact and opinion are the responsibility of the authors alone and do not imply an opinion on the part of the officers or the members of the ACP. The ACP Messenger annual subscription rate for members is \$45, which is included in membership dues. The U.S. subscription rate for Prosthodontic Forum Organization members is \$55 and \$65 for non-members. Canadian subscribers add \$5 each year; all other non-U.S. subscribers add \$10 each year.

The ACP Messenger (ISSN # 0736-346X) is published four times per year in the winter, spring, summer, and fall by the American College of Prosthodontists:

211 E. Chicago Ave., Suite 1000, Chicago, IL 60611

Phone: (312) 573-1260 Fax: (312) 573-1257

Email: acp@prosthodontics.org Website: Prosthodontics.org

© Copyright 2018 American College of Prosthodontists. All rights reserved. Materials may not be reproduced or translated without written permission. Contact the ACP for reprint permission.


Postmaster: Send address changes to the ACP Central Office at 211 East Chicago Avenue, Suite 1000, Chicago, IL 60611 or acp@prosthodontics.org.

On the cover: Full-wax try-in visit and shade analysis for hybrid implant prosthetics
Photo credit: Miles R. Cone, DMD, MS, CDT, FACP



Margie Arnett is an interprofessional education specialist at the University of Arizona and the founder of Giddyup Genie, a digital marketing and website design company.

► Page 16




Dr. Armand Bedrossian is a recent graduate from the prosthodontics program at the University of Washington.

► Page 12




Dr. Avinash S. Bidra is Program Director of the Prosthodontics Residency Program at the University of Connecticut Health Center School of Dental Medicine. He serves as Co-Chair of National Prosthodontics Awareness Week.

► Page 26



Dr. Miles R. Cone serves as Editor-in-Chief of the *ACP Messenger*. He maintains a private practice in Portland, Maine.

► Page 6



Dr. Luiz H. Gonzaga serves as Assistant Professor, Center for Implant Dentistry at the University of Florida.

► Page 8



Dr. Leonard B. Kobren maintains a private group practice in White Plains, New York. He is Chair of the ACP Education Foundation.

► Page 20



Dr. Robert M. Taft is President of the ACP. He serves as Chair of the Department of Comprehensive Dentistry at the University of Texas Health Science Center, San Antonio.

► Page 18



Dr. Elaine Torres-Melendez maintains a private practice in Yardley, PA. She serves as Co-Chair of National Prosthodontics Awareness Week.

► Page 26



MAKE THE MOST OF YOUR DENTAL CAREER.

As a prosthodontist on the U.S. Army or Army Reserve health care team, you'll have opportunities to work with some of the most innovative technology in the industry, practice at world-class dental facilities, all while developing advanced dental skills that you can use every day. There are also opportunities for a paid, full-tuition scholarship, a special bonus, education loan repayment and paid continuing education. But most importantly, you'll see the greatest reward in the smiles you've restored for Soldiers and their families.

To find out more about the numerous positions available worldwide, visit us at healthcare.goarmy.com/dental or contact your local U.S. Army Recruiter.



U.S. ARMY



Same planet, different worlds

Miles R. Cone,
DMD, MS, CDT, FACP
ACP Messenger Editor-in-Chief

Our specialty training is at once a blessing and a curse. There is no part of comprehensive dental esthetics that escapes the prosthodontist's eye, and we are thoroughly brainwashed to obsess over the nuances of tooth position, incisal edge morphology, shade analysis, and facial proportions.

Our patients, on the other hand, obsess over the banality of a straighter, whiter, and largely underwhelming dentition. How many times have you constructed a maxillary denture for a patient only to have them tell you that the ideally sized centrals you've selected make them look like a rabbit? How many times has your patient bemoaned the translucency and mamelons layered into their gorgeous ceramic crowns? For me...too often.

Aside from our patients, prosthodontists also view the human dentition through an entirely different lens than the general dentist, orthodontist, periodontist, and so on. Nowhere else within the profession is the artistic expression of the science of dentistry so amplified as it is in prosthodontics. Amongst our peers, we truly inhabit the same planet, yet very different worlds. During my residency, a mentor once remarked that "It is truly unfortunate we don't make teeth for other prosthodontists." Real talk.

Our media-gripped society is largely to blame in the ongoing race to the bottom to see who can achieve the most unnaturally uniform and homogeneous smile first. After all, perception is reality. However, this is an irresponsible accusation that drips with subjugated culpability. As the subject matter experts, the onus of obligation falls on the shoulders of prosthodontists to educate our patients to view teeth for what they are:

biologically unique and individually specific integrated components of a whole human being – not anatomical accoutrements that can be mass-produced to suit the current cosmetic cliché (see comedian Steve Harvey for perhaps the most egregious example of this). If a sea change in the cultural zeitgeist of current tooth trends is every going to occur, it will begin with our specialty turning the tide.

The rising waters in the summer issue of the *ACP Messenger* feature Dr. Luiz Gonzaga, who exposes the art and science behind various aspects of dental photography and discusses how to influence team communication and patient education. Dr. Armand Bedrossian discusses the role that hard and soft tissue integration plays in complex treatment planning and the predictability and reality of dental implants for full-mouth rehabilitations. And lastly, Margie Arnett outlines social media marketing strategies to educate, engage, and connect with prospective patients.


When it comes to reconstructing and replacing the oral architecture for our patients, we are perfectly positioned to show each individual that which they didn't know even existed. As food for thought in this regard, consider the words of Henry Ford who famously stated that "If I had asked people what they wanted, they would have said faster horses." ■



COPYRIGHT
CLARE B. INOT
WASHINGTON, D.C.

"IF I HAD ASKED PEOPLE WHAT THEY WANTED, THEY WOULD HAVE SAID FASTER HORSES."

- HENRY FORD



4 CYL. MODEL T
FORD, 1908

© The GROGAN PHOTO COMPANY Danville, Ill.

Dental photography: the flash war

Luiz H. Gonzaga,
DDS, MS

Dental photography is very relevant in many aspects of prosthodontics, from data collection, treatment planning, and team communication to patient education, medico-legal records, and marketing. The pursuit of a better picture leaves us always looking for the best trick or equipment. One of the polarizing topics in dental photography is what type of camera flash reigns supreme?

Many aspects of photography are important to achieve great results, such as the type of lens, the camera sensor, camera settings, and of course photographic techniques; however, many agree that the most important would be the light source.

The light source in dental photography is considered more critical, since intraoral photography is akin to taking photos inside a dark cave. We could say that the ring flash is the workhorse of our light armamentarium, however there is an emergent popularization of the so-called twin flash. This article will discuss the pros and cons of each one and will hopefully help you to implement the best fit for you.

As mentioned, the ring flash is the most commonly used light source for dental macro photography. The ring flash is typically built with two lamps inside a circular case that defuses the light circumferentially and is mounted very close to the end of the lens. The nature of this light allows for a very uniform distribution of the light and elimination of most shadows which is ideal for medico-legal documentation (Figure 1). That lack of shadows give us the ability to visualize large portions of the oral cavity, especially the most distal ones, however the absence of shadows creates a flat image with a lack of three-dimensional

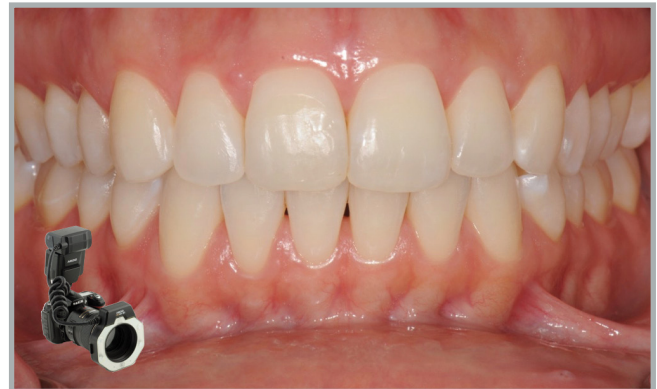

Fig. 1: Ring flash allows for uniform distribution of light.

depth perception. The ring flash can also create large specular highlights when the light hits a reflecting surface of the tooth. This effect can be minimized by changing the angulation of the camera or even by removing the ring flash from the front of the lens and holding the flash off to the side of the camera at an angle, or using cross polarization.

On the other hand, the twin flash involves two independent light sources that can be positioned in various angles (Figure 2). The ability to position the light source to complement the position of the camera, well demonstrated by Edward Maclaren, Sasha Hein, and others, allows for photographs with more selective highlights and shadows, which gives the dental



Fig. 2: Various flash angles.

structures a more three-dimensional appearance and can enhance the perception of surface texture (Figure 3). By controlling the highlights through the position of the flash, specular reflections can be greatly reduced to expose internal characteristics of the teeth, which is essential in shade matching. The drawback of a twin flash set-up includes the challenges in illumination of the most distal structures and buccal corridor when compared to the ring flash (Figure 3a).

The twin flash can also allow for greater creativity when you wish to “soften” the light more with bouncers or diffusers. The use of “soft boxes” is quite simple and inexpensive with twin flashes (Figure 4). It is important to remember that light modification almost always results in changes to the kelvin temperature of the light. Both ring and twin flashes produce a light with approximately 5500K, and if your camera was adjusted to match this, the use of bouncers or soft boxes will change the light temperature and can significantly alter the color accuracy of your photograph. This is a problem that can be easily overcome; however it is important to be aware of this, especially when using photography for shade matching.

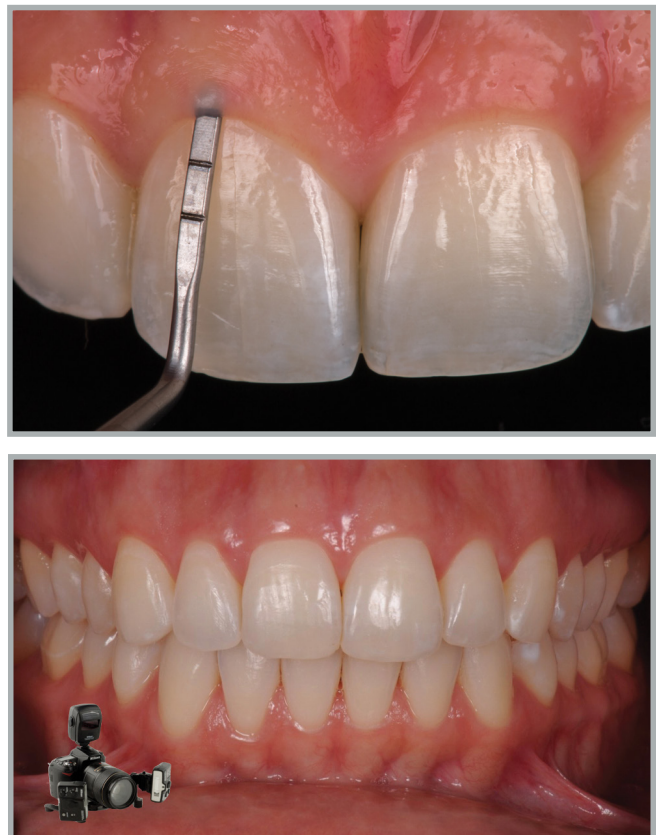


Fig. 3 (top): Twin flash enhances the perception of surface texture.

Fig. 3a: Twin flash includes challenges in illumination.

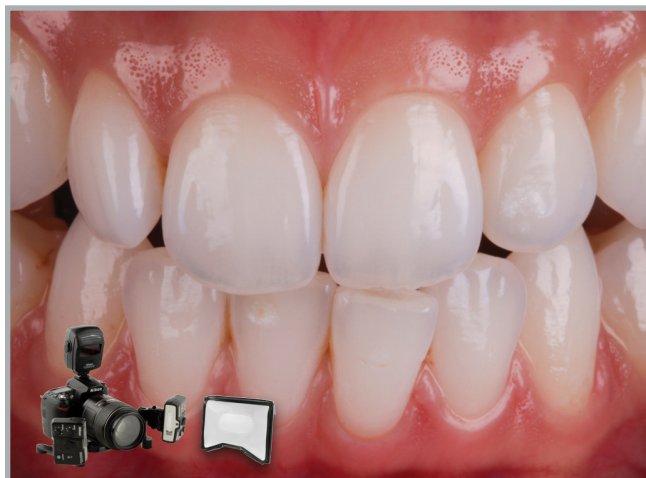

Fig. 4: Twin flash with soft box.

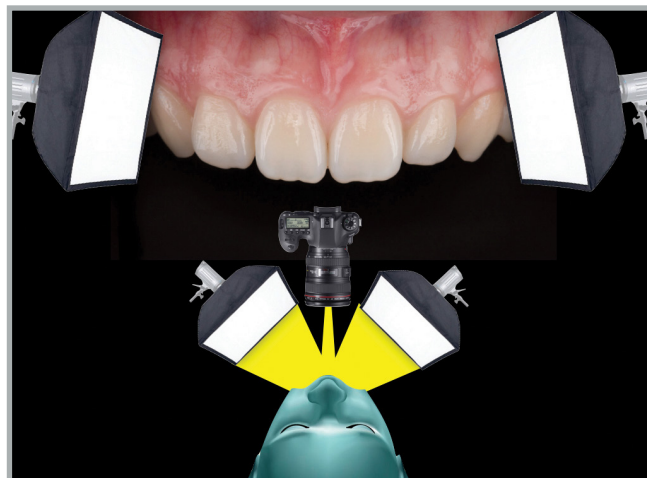


Fig. 5: Studio flash with soft box.

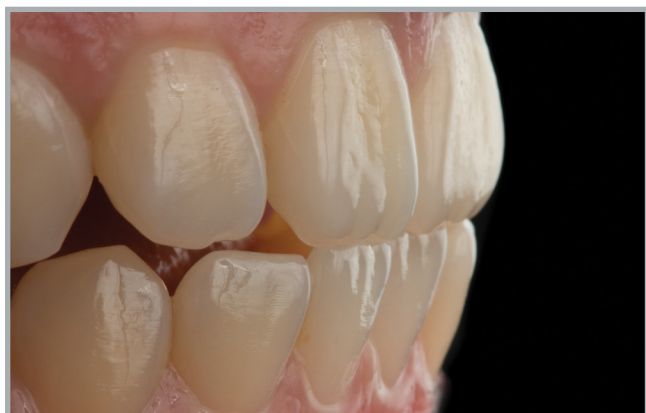

Fig. 6: Studio strobe lights produces photos for presentations or social media.

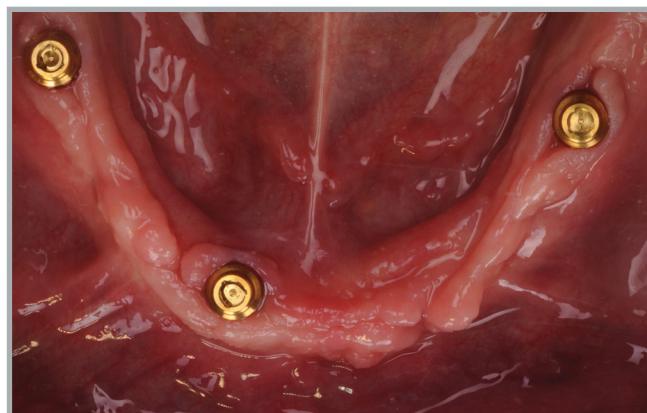


Fig. 7: Outcome using twin flash.

Another option that is not that common in everyday practice is the use of studio strobe lights. These types of lights can produce great illumination with a very soft effect and with very large diffuse and less harsh reflections (Figure 5: Photo done in collaboration with Dr. Adam Hamilton). The results produced with this technique can be great in some aspects, but the results will never reproduce a realistic situation. These are great photos for presentations or social media posts but do not represent how our eyes will perceive the teeth or tissues (Figure 6: Photo done in collaboration with Dr. Adam Hamilton).

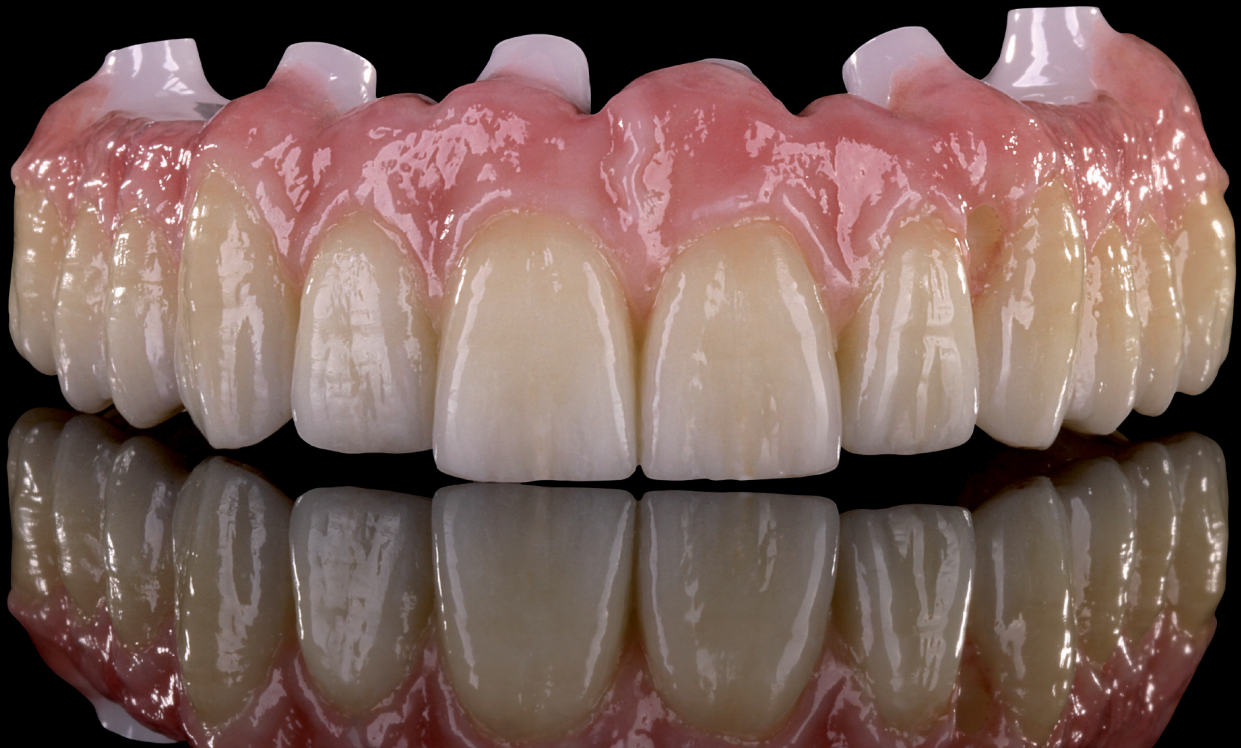I think it is fair to say that the ring flash is a more straightforward light source to be used in dental photography, especially for the novice photographer, but it has some limitations and will maybe not communicate texture details or produce the “WOW effect”. In contrast, the twin flash is a more versatile light source with multiple options for modifications and allows for more ways to express your creativity (Figure 7). For the operator, it requires a better understanding of illumination and can be frustrating sometimes when taking photos of the posterior regions or with mirrors. ■

Zirkonzahn®

HIGH QUALITY BY ZIRKONZAHN

Prettau® Bridge with anodized titanium bases

Milled in your in-house laboratory



Zirkonzahn USA Inc. – Phone +1 800 989 8931 – Phone +1 678 441 9419 – infousa@zirkonzahn.com
Zirkonzahn Worldwide – Phone +39 0474 066 680 – info@zirkonzahn.com – www.zirkonzahn.com

What happens when the implant fails?

Armand Bedrossian,
DDS

Replacing or restoring a single central incisor is arguably the most difficult task to achieve in esthetic dentistry. Multiple factors play a role in achieving an esthetic outcome, such as tooth proportions, form, and color, as well as gingival display, soft tissue level, color, and contour. The advancement in surgical techniques and implant procedures has provided more predictable outcomes; however, complications are inevitable and alternative treatment modalities must be discussed with the patient if and when things go awry.

This article will review how to evaluate the hard and soft tissues in the esthetic zone and discuss ways to prosthetically compensate for hard and soft tissue deficiency while providing an esthetic outcome that meets the patient's expectations.

It is important to understand the intersection between reality and predictability. The Pink Esthetic Score (PES) is a post-operative assessment of the soft tissue around single implants.¹ The assessment is based on 7 criteria of the soft tissue; each criterion scoring either a 2-1-0, with 2 being the best and 0 being the poorest score. An excellent score is a 14, but the threshold for esthetic acceptability is considered at least a 7 out of 14. Since expectations of patients for an esthetically pleasing outcome can be unrealistic, using the PES as a pre-operative assessment of the existing soft tissue can allow for better patient communication, reasonably achievable expectations, and predictable post-treatment outcomes.

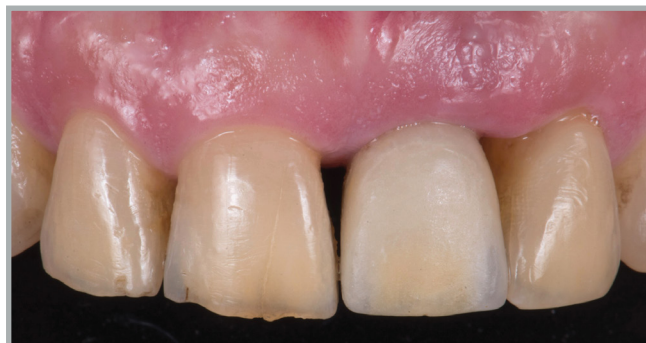

Fig. 1: Implant provisional crown at site #9 shows the initial patient presentation after the completion of orthodontic therapy.

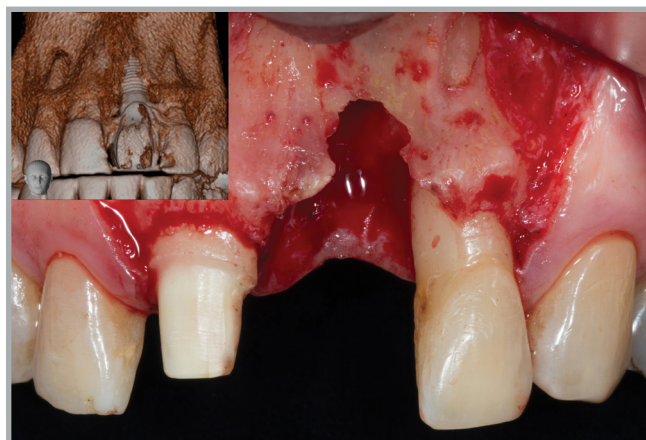

Fig. 2: Immediately following implant removal.

Variables	0	1	2
Mesial papilla	Absent	Incomplete	Complete
Distal papilla	Absent	Incomplete	Complete
Level of soft tissue-margin	Major discrepancy >2mm	Minor discrepancy 1-2mm	No discrepancy <1mm
Soft tissue contour	Unnatural	Fairly natural	Natural
Alveolar process	Obvious	Slight	None
Soft tissue color	Obvious difference	Moderate difference	No difference
Soft tissue texture	Obvious difference	Moderate difference	No difference

Table 1: Soft and hard tissue evaluation for implant provisional restoration shown in Fig. 1, providing a cumulative PES of 9. This score represents a baseline for esthetic predictability.

Our patient presents for full-mouth rehabilitation. The implant provisional crown at site #9 (Figure 1) shows the initial patient presentation after the completion of orthodontic therapy. Since the implant has been restored, albeit with a provisional abutment and crown, we can apply the PES as shown in Table 1.

A modified PES (since this is the provisional restoration) resulted in a score of 9/14, which is in the range of esthetic acceptability. Shortly after this, a fistula tract developed and a diagnosis of peri-implantitis was made. The clinical decision to remove the implant was made (Figure 2) and guided-bone-regeneration (GBR) was performed at the time of implant extraction.

Six months after implant removal and bone augmentation, the patient presents as a “new” patient with a missing tooth in the esthetic zone with the adjacent tooth prepared for a full coverage restoration (Figure 3). Our goal at this point is to assess the soft tissue relative to the PES if an implant were to be placed (Figure 4). This pre-operative baseline score

provides some idea of what is achievable in terms of an esthetic outcome (Table 2). In this situation, the result was a PES of 2, which would be considered an esthetic failure for an implant-supported single crown.

At this point, it is essential to discuss the various treatment options for restoring the edentulous site, since the likely outcome for an implant is below the esthetic acceptability threshold. The two most obvious options are surgical hard and soft tissue reconstruction prior to implant placement or a conventional fixed partial denture (FPD) with an ovate pontic. However, the unpredictability of reconstructing the hard and soft tissue defect with compromised proximal bone heights of the adjacent teeth, and the expectation of an acceptable esthetic outcome, will influence the patient’s decision. Moreover, prosthetic reconstruction with a three-unit FPD, may allow the restorative material to compensate for the lack of hard and soft tissue. The indications for a tooth-supported FPD versus a single implant crown have been thoroughly investigated in the literature, and have found no

Variables	0	1	2
Mesial papilla	Absent	Incomplete	Complete
Distal papilla	Absent	Incomplete	Complete
Level of soft tissue-margin	Major discrepancy >2mm	Minor discrepancy 1-2mm	No discrepancy <1mm
Soft tissue contour	Unnatural	Fairly natural	Natural
Alveolar process	Obvious	Slight	None
Soft tissue color	Obvious difference	Moderate difference	No difference
Soft tissue texture	Obvious difference	Moderate difference	No difference

Table 2: Soft and hard tissue evaluation for situation shown in Fig. 4, providing a cumulative PES of 2. This score is below the esthetically predictable threshold.

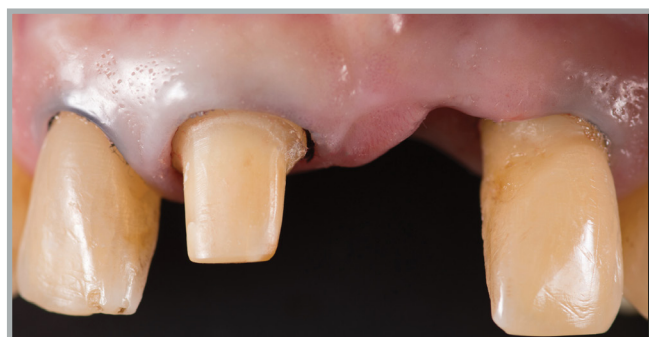

Fig. 3: Patient presents as a “new” patient with a missing tooth in the esthetic zone with the adjacent tooth prepared for a full coverage restoration.

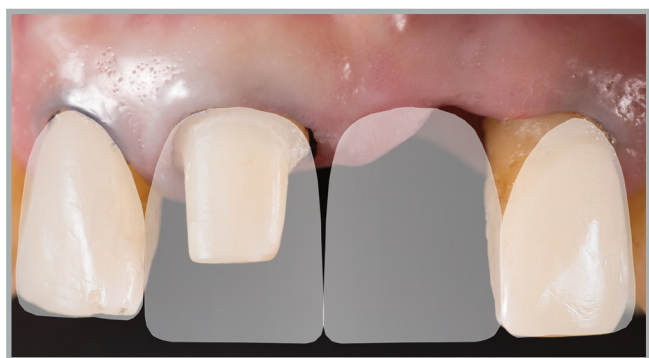

Fig. 4: A new PES evaluation, post implant removal.

difference in survival between the two treatments.^{2,3,4} Belser et al, suggested that optimal prosthetic design should be dictated by local factors, such as the quality and quantity of bone, periodontal condition of the teeth, interdisciplinary care to optimize the implant site, and esthetic predictability.⁵ This factor, in conjunction with the low PES of 2, leads the decision towards a FPD.

The absence of adequate hard and soft tissue makes it very difficult to create appropriate tooth form without also including prosthetic gingiva or root form into the design (Figure 5). As challenging as it may be, the reconstructive team (prosthodontist, periodontist, and lab technician) must all understand the components of a smile, including the three dimensions of tooth and gingival form.^{6,7} Additionally, a properly contoured provisional restoration will allow for conditioning and reshaping the soft tissue for an acceptable esthetic outcome.⁸ Initially, no gingival colored resin was used in the provisional restoration. But at the try-in stage of the final restoration, the gingival embrasure had been opened enough that it created a “black triangle” and even more of a shadow that was evident

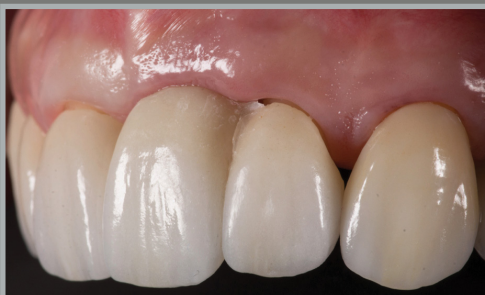
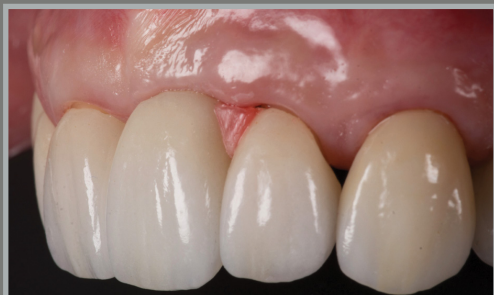
Fig. 5: The use of red and white wax allows the patient and clinician to visualize the use of pink or white prosthetics at the compromised site.

in the provisional restoration. After showing this to the patient, he wanted to know what it would look like with gingival colored porcelain. In this case, with the definitive restoration in a bisque stage, red and white rope wax was used to simulate either papillae or root form to conceal the deficiency (Figure 5). After seeing this, the patient chose white ceramics to mimic recession and root eminence. The prosthesis was then shaped to mimic root form and characterized using extrinsic stains (Figure 6). The final result is shown in Figure 7. ■

*Special thanks to Bobby Williams,
CDT at Synergy Ceramics.*

References:

1. Furhauser, Florescu, et al. Evaluation of soft tissue around single-tooth implant crowns: the pink esthetic score. *Clin. Oral Impl. Res* 16, 2005:639-644.
2. Sadowsky SJ, Bedrossian E. Evidence-based criteria for differential treatment planning of implant restorations for the partially edentulous patient. *Journal of Prosthodontics*. 2013.
3. Pjetursson, BE, Bragger U, et al: Comparison of survival and complication rates of tooth supported fixed dental prostheses (FDPs) and implant-supported FDPs and single crowns (SCs). *COIR* 2007;18(Suppl.3):97-113.
4. Jøstad A: After 10 years seven out of ten fixed dental prostheses (FDP) remain intact and nine out of ten remain in function following biological and technical complications that have been repaired. *J Evid Based Dent Pract* 2010;10:39-40.
5. Belser UC et al: Outcome analysis of implant restorations located in the anterior maxilla: A review of the recent literature. *IJOMI*, 2004; 19(Suppl):30-42.
6. Coachman C, et al. Prosthetic gingival reconstruction in a fixed partial restoration. Part 3: Introduction to artificial gingival as an alternative therapy. *Int J Periodontics Restorative Dent*. 2010;30:3-13.
7. Cronin RJ, Wardle WL. Loss of anterior interdental tissue: Periodontal and prosthodontic solutions. *JPD*, 1983, Oct;50(4):505-509.
8. Haj-Ali R, Walker MP. A Provisional fixed partial denture that stimulates gingival tissue at the pontic-site defect. *J. Prosthodont* 2002, March; 11:46-48.

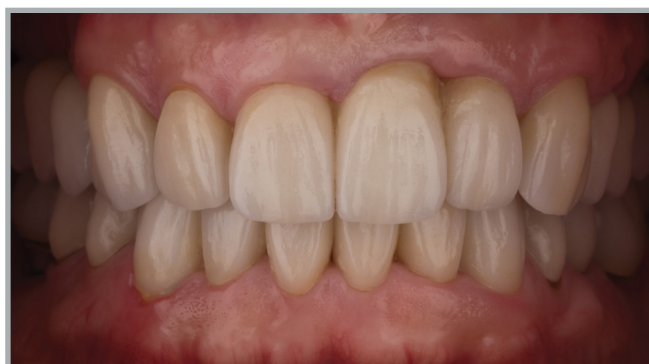

Fig. 6: Prosthesis shaped to mimic root form and characterized using extrinsic stains.

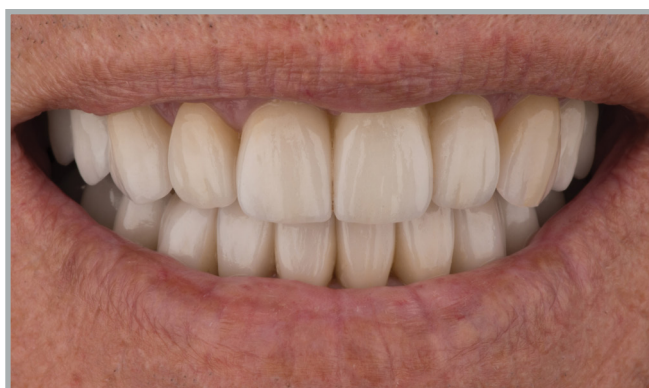

Fig. 7: Final result.

Have you lost faith in Facebook?

Margie Arnett, MS

With concerns over privacy and data, how important is having your practice on Facebook? This article will share information about the social media landscape and how to increase engagement.

Facebook has been challenged by consumers with privacy concerns over data breaches and trustworthiness like fake news and Russian trolls. While Facebook has the ability to give users control of their private data, they are not required to do so. Facebook CEO Mark Zuckerberg recently addressed the Cambridge Analytica data breach and their responsibility to protect user data.

Should you continue using a Facebook business page?

BuzzSumo analyzed over 880 million Facebook posts by brands and discovered a 20% drop in the average number of engagements since the start of 2017.¹ But Facebook will continue to be a viable inbound online destination that many users will continue to enjoy, complete with inexpensive targeted advertisements for businesses. Many web-based and mobile applications are fully integrated with and require a Facebook account. Our culture has adapted around Facebook, and Facebook's 2018 first quarter operational highlights agree.² A recent Pew Research Center survey reported that Facebook continues to dominate the social media landscape with 68% of U.S. adults using a Facebook account, and 74% of those users access Facebook daily (Figure 1).³

Majority of Americans now use Facebook, YouTube

% of U.S. adults who say they use the following social media sites online or on their cellphone

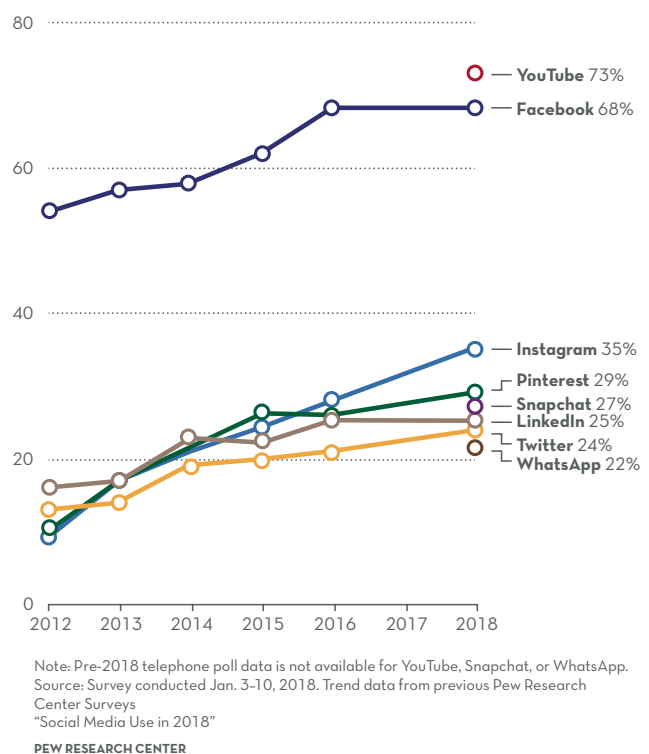


Fig. 1: Americans' preferred social media applications.

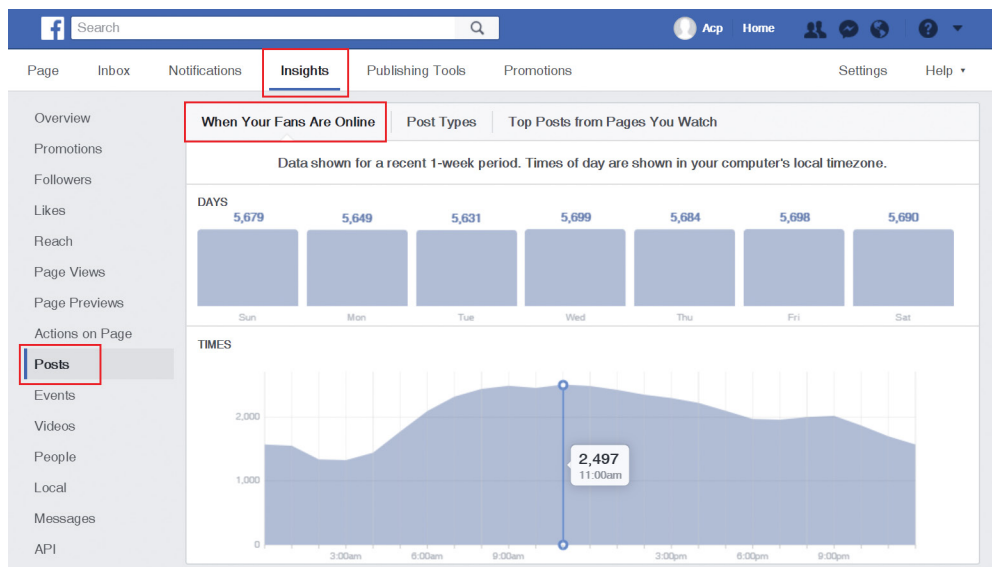
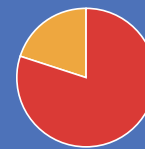

Fig. 2: When your Facebook fans are online.



Sales

Keep the 80/20 rule here. Most of the time, you should provide information by posting a combination of tips, how you solve dental problems, memes or cartoons, and recognition of holidays. The other 20% of the time, you can promote your services.

8 Ways to Increase Facebook Engagement

- 1. Post when your fans are online.** The best way to determine the time is by viewing your Facebook data. Click Insights at the top of your Page. Click Posts on the left. The first section is When Fans are Online, which shows a weekly snapshot (Figure 2).
- 2. Solve problems and provide tips.** Customers/patients often ask:
 - a. Does this person understand my needs?
 - b. Can this person solve my problem(s)?
 - c. Do I like and trust this person?
- 3. Be authentic and build trust.** Dentistry makes some patients anxious, and many of you have created calm, relaxing office environments. Posting about your headphones, an in-office water feature, premium dental chairs, relaxing fish tanks, or your appreciation of office staff makes you more relatable. But, if your staff doesn't want their picture online, don't force the issue.
- 4. Reply to comments, questions, and concerns, but don't forget HIPAA.** Failure to write back is almost like receiving a birthday gift and not writing a thank you note.
- 5. Your practice phone number and website should be included on most posts, since posts are readily shared across Facebook.**
- 6. Promote your page at your place of business and ask satisfied customers for an online review.**
- 7. Promote your page with contests and giveaways.** Facebook has a number of rules and my suggestion is to use a professional-looking application to run your contests, like Wildfire.
- 8. Use photos and selfies in your posts!** Place a couple of selfie sticks in the office to encourage patients to take photos and check-in on your page. Don't post pictures of patients without their written consent! ■

References:

1. Rayson, S. Facebook Engagement for Brands and Publishers Falls 20% in 2017. Buzz Sumo, August 29, 2017. At: <http://buzzsumo.com/blog/facebook-engagement-brands-publishers-falls-20-2017/#gs.jX3RYPI>. Accessed May 10, 2018.
2. Facebook Reports First Quarter 2018 Results. (Press Release), NewsWire, April 25, 2018. At: <https://investor.fb.com/investor-news/press-release-details/2018/Facebook-Reports-First-Quarter-2018-Results/default.aspx>. Accessed May 10, 2018.
3. Smith, A., Anderson M. Social Media Use in 2018. Pew Research Center: March 1, 2018. At: <http://www.pewinternet.org/2018/03/01/social-media-use-in-2018/>. Accessed May 10, 2018.

Choose to be the bus driver

Robert M. Taft,
DDS, FACP
ACP President

As a specialty, prosthodontics continues to drive innovation in patient care. In education, research, and advancement of the specialty, the first-ever joint strategic plan of the ACP and the ACPEF will support our move from a tactical orientation to one that is more strategic in posture.

For this move to be meaningful in each of our own lives, we as individuals need take this challenge to heart. Whether you are in private practice, education, federal services, or a combination thereof, your area of focus will require its own approach, but it will share with other areas of our specialty the common core of active, engaged leadership.

So why have I asked you to choose to be a bus driver? Because we, as prosthodontists, need to drive innovation for more than just ourselves. Like a bus driver, you are in control of the direction and speed, and you will bring passengers on board with you.

What does active, engaged leadership look like? According to FedEx, its best leaders share nine personal attributes. Judge yourself against these (edited) descriptions of the nine faces of leadership:

Charisma: Instills faith, respect, and trust. Has a special gift of seeing what others need to consider. Conveys a strong sense of mission.

Individual consideration: Coaches, advises, and teaches people who need it. Actively listens and gives indications of listening. Gives newcomers a lot of help.

Intellectual stimulation: Gets others to use reasoning and evidence, rather than unsupported opinion. Enables others to think about old problems in new ways. Communicates in a way that forces others to rethink ideas that they had never questioned before.



Courage: Willing to stand up for ideas even if they are unpopular. Does not give in to pressure or to others' opinions in order to avoid confrontation. Will do what's right for the company and for employees even if it causes personal hardship.

Dependability: Follows through and keeps commitments. Takes responsibility for actions and accepts responsibility for mistakes. Works well independently of the boss.

Flexibility: Functions effectively in changing environments. When a lot of issues hit at once, handles more than one problem at a time. Changes course when the situation warrants it.

Integrity: Does what is morally and ethically right. Does not abuse management privileges. Is a consistent role model.

Judgment: Reaches sound and objective evaluations of alternative courses of action through logic, analysis, and comparison. Puts facts together rationally and realistically. Uses past experience and information to bring perspective to present decisions.

Respect for others: Honors and does not belittle the opinions or work of other people, regardless of their status or position

How did you do? As a prosthodontist, I have found many of these principles natural to what we do and who we are, making strategic positioning less cumbersome and more effective. These principles can and should be valuable in any professional setting.

I have often wondered what made some leaders more effective than others. An Army Colonel once shared his thoughts on the subject with me, which I'll paraphrase as "An Act in Four Seens":

The first is "**Being Seen**". The best attribute a leader can emulate in any position of authority is to be seen. This forms the foundation for a set of behaviors that will maintain success throughout a leader's tenure.

The second is "**Seen seeing**". This is most often observed as "Leadership by walking around". This allows you to get to know the people on a more personal basis and observe the day to day operations. It validates your position and interest in the organization not to mention the value you place on each individual.

The third is "**Seen listening**". It is important for a leader to get to know an organization before trying to execute new ideas so as to place slight course

adjustments rather than redirection in order to meet mission. People will not be pushed by a new leader before they have decided consciously to follow them. They will sooner follow someone whom they believe has listened to their concerns and ideas rather than one who has dreamed up their own.

The fourth is "**Seen doing**". The ultimate contribution a leader can make is to move the organization forward with passion and persistence that will meet the challenges of today and the future, always working on the long term goal.

Each one of us is distinctive in the way we carry out our mission. We should cultivate these principles of leadership as we are in the business of service to each other and to our patients. By bringing others on board and strengthening the "WE", we can make our College a stronger, more vibrant, and dynamic organization.

Choose to be the bus driver – and help move our specialty forward. ■

This article is dedicated to the 2016-2018 NPDS prosthodontics residents whose drive and professionalism continues to inspire me everyday. The bus you see here was developed thorough a complete digital workflow.

Has there ever been a better time to be a prosthodontist?

Leonard B. Kobren,
DDS
ACPEF Chair

Today, the baby boomers have the time and financial capability to enhance this period of their lives in ways never before imagined. They are living longer, but as children and young adults, many did not have the benefit of fluoride, sealants, or access to today's knowledge of prevention and oral care. They require the diagnostic and restorative skills that are the essence of prosthodontic education.

Above all else, time may be considered their most valuable commodity. The digital world that frees up their time for enjoyable pursuits is fully present in prosthodontics. Much like the introduction of implants in the 1980s, digital dentistry and artificial intelligence will dominate the ways in which diagnosis is made and treatment is rendered.

Our specialty's leadership in the development and launch of the transformative Digital Dental Curriculum in partnership with Henry Schein and its partner companies will impact the entire dental profession's delivery of patient care. The incredible speed and efficiency with which this was achieved adds to the recognition of prosthodontists as leading the evolution in total oral health and its relationship to overall wellness.

The growth of the Foundation has allowed the support more than 200 research projects. It funds the ACP membership dues for all postdoctoral students and provides travel stipends for more than 300 students to attend the Annual Session. We are the only specialty to host two yearly educators meetings with participation from more than 90% of all undergraduate restorative and post-graduate prosthodontic programs.

While the opportunities for prosthodontists are substantial, there are headwinds that the College and Foundation are aligned to confront. The merger of many of our most loyal corporate supporters has

altered the landscape and intensified the need for increased synergistic creativity. Facilitating the inclusion of the digital future into private practices will improve patient care and ensure that our practices are viable and relevant for our new colleagues to join, invest, and transition into. The ACP and ACPEF's strategic plan for 2019-2021 includes priorities that have been specifically designed to address our individual members and the specialty's current and future needs.

I am delighted to report that last year the Annual Appeal received a record number of 523 member donations with a generous average of \$330. A total of \$172,898 was realized. Imagine if 2500 more members each donated \$100. That would mean more than \$400,000 to support innovative educational opportunities, explore the ramifications of artificial intelligence, create additional research opportunities, and much more.

As Warren Buffett said, "Ultimately there is one investment that supersedes all others: invest in yourself." As we increase the collective investment in ourselves, we also create a compelling reason for our corporate supporters to continue their investment in our mutual vision and mission.

Please celebrate the successes of our specialty and the anticipated needs of our future by joining our colleagues who have donated with passion and an understanding of the relevance and importance of self-investment. ■

Congratulations
to the
***American College
of Prosthodontists
and its Education Foundation***

for the groundbreaking release of the new
Digital Dentistry Curriculum

Henry Schein and our
valued supplier partners
**3Shape, BioHorizons, CAMLOG,
Glidewell Dental, and Planmeca**
are honored to support an initiative
that helps prepare students for success
in today's digital world.

***Because so many rely on you,
you can rely on us.***



Contact us at:
www.henryscheindental.com

Prosthodontists pick Baltimore's best

It's been cited as one of the most exciting food cities and art scenes in America, and Baltimore has plenty to enjoy while you're in town for the 2018 Annual Session, Oct. 31-Nov. 3. We asked a few of your fellow members for some tips to help make the most of your trip.



Dr. Heather Lynn Giannotta

Maryland is famous for blue crabs, oysters, and rockfish. Be sure to try the blue crab and compliment the flavors with the official beer of Baltimore, National Bohemian Beer – colloquially a “Natty Boh”.

If you want to enjoy the waterfront views just take a stroll along Baltimore's Inner Harbor. Even if you are not an Orioles fan, you can enjoy a signature Maryland drink called an Orange Crush. The city has reconditioned several historic ships into museums that visitors can climb aboard and experience maritime history firsthand.

A list of my favorite things to see and eat is posted at acp48.com. For fine dining, the Bygone has the best view in Baltimore, at the top of the Four Seasons Hotel.

Dr. Radi Masri

The Inner Harbor is a hub for sightseeing and full of attractions. It features the National Aquarium with its giant turtles, sharks, dolphins, and electric eels. There is also the Maryland Science Center, Port Discovery, historic warships, and Power Plant Live, which is a former power station that now houses restaurants, bars and music venues. The Water Taxi offers a quick and safe way to get around the Baltimore Harbor.

A short walk from the Inner Harbor, the Dr. Samuel D. Harris National Museum of Dentistry features George Washington's teeth and the amazing teeth feats of circus performer Penny Wilson, as well as hands-on exhibits about healthy smiles. Make sure to call for an appointment before visiting.

Little Italy is the home of numerous restaurants offering homestyle Italian cuisine, bakeries as well as as delis. Attractions include the Star-Spangled Banner Flag House, Reginald F. Lewis Museum of Maryland African American History & Culture, and the Baltimore Civil War Museum.

Federal Hill is a walkable neighborhood with great views of the Baltimore Harbor. It is known for its Cross Street Market, quirky storefronts, and the American Visionary Art Museum.

Then there's the B&O Railroad Museum, a national landmark with a vast archive of locomotive artifacts.



Dr. Carl Driscoll & University of Maryland Residents

All of these are within walking distance of the meeting:

The best restaurant in Maryland is Charleston, led by James Beard-winning chef Cindy Wolf. It's a high-end meal at a high-end price. Worth the experience but book ahead. Also in Harbor East 9 are Oceanaire Seafood, an upscale choice for seafood and steaks, and Cinghiale, a lively wine bar and formal restaurant serving a daily menu of upscale Italian cuisine in stylish digs.

It's a three-minute walk to Little Italy, an old-style Italian neighborhood with great, inexpensive food and lots of stoops. Amicci's is a favorite because of their "pane rotunda", a mound of bread covered with a delicious creamy garlic shrimp sauce. Vaccaro's is the place to get fresh made cannoli, cookies, and other Italian treats.

For meat lovers, take your pick of Ruth's Chris, Flemings, Capital Grille, and Morton's in the Inner Harbor.

For breakfast, it's a short taxi ride to Blue Moon Café, a unique breakfast experience as seen on *Diners, Drive-ins and Dives*. Very small but worth the wait. Miss Shirley's Café is the place for down home American breakfasts and more.



It happened here first

For almost 250 years, Baltimore has been known for breaking new ground in science and technology. Here are a few of the historic firsts that occurred in Charm City:



1774

First Post Office system in the U.S.



1792

First water company chartered in the U.S.



1840

World's first dental college:
Baltimore College of Dental Surgery



1844

World's first telegraph line, between
Baltimore and Washington, D.C.



Getting Your Paper Published: Writing and Revising Your Research

Friday, Nov. 2, 12:00 – 2:00 p.m.

This workshop, aimed at residents and early career academics, will provide insight into preparing research for publication, including writing and revising. *Journal of Prosthodontics* editors will discuss tips for writing and submitting research and review common mistakes found in manuscripts.

Clinical trials and human subject research, including ethical considerations, advantages and disadvantages, and reasons to conduct each study type, will be discussed. Add this workshop to your Annual Session registration at acp48.com. Lunch will be provided.

Digital Poster Session for Residents & Dental Students

Leave the printers and poster tubes behind! At the Annual Session in Baltimore, the Poster Session will be presented on digital monitors.

Eligible residents and dental students are invited to submit an abstract. Presentations are intended to highlight scholarly activity, promote research, and engage students. Topics may include research results, clinical outcomes, laboratory techniques, or other areas of interest to ACP members and guests.

Visit acp48.com for submission guidelines and how to submit your abstract through the online ePosters system.

Abstracts are due by Sept. 14. ■



48TH ANNUAL SESSION
OCT 31-NOV 3 • BALTIMORE



Innovative Applications in Prosthodontics

Oct. 31-Nov. 3

Baltimore

*Bone Augmentation: Science
and Application*

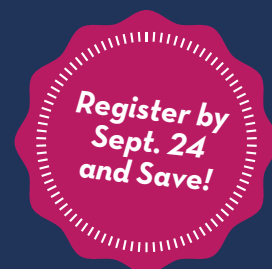
Dental Implants: State of the Art

Dental Implants: Complications

Advances in Prosthodontics

*Advanced Dental Materials
and Technology*

acp48.com



A unified message


Avi S. Bidra, BDS, MS, FACP

NPAW Co-Chair

Elaine Torres-Melendez, DMD, FACP

NPAW Co-Chair


We are happy to report that NPAW 2018 had the highest level of participation by ACP membership to date! Members of every ACP region participated in an effort to raise awareness of our specialty and emphasize a unified message that prosthodontists are the specialists for the replacement of missing teeth. It is after all prosthodontists who care about increasing the awareness of prosthodontics!



Pennsylvania



Georgia



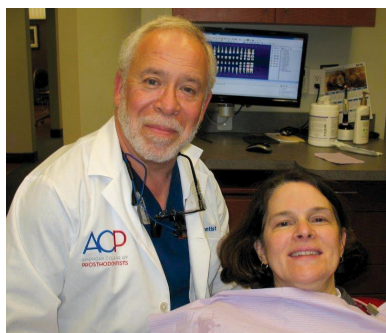There were over 22,000 interactions with NPAW posts on social media and official proclamations were presented to a population of over 9 million people. Prosthodontists offered pro bono services and informational talks, sent Letters to the Editor, and hosted open houses. We continue to promote our specialty as a group and on an individual basis. A successful public relations campaign is ongoing and is undertaken by our members at no extra cost to the ACP budget! With help from the ACP Central Office, our NPAW Toolkit went digital, with new content added and previous content reorganized to make it easier to navigate and use.

We thank all of you who participated in this initiative and continue to promote awareness of our specialty throughout the year and are looking forward to even more successful NPAWs in the years to come.

OVER **350 MEMBERS**
PARTICIPATED IN NPAW
ACTIVITIES



Alabama



New Jersey



Florida

OFFICIAL PROCLAMATIONS MADE COVERING 9 MILLION PEOPLE

Please enjoy some of the highlighted activities presented below. More activities can be found on the ACP website at prosthodontics.org/npaw.

Region 1

Connecticut: Dr. Marie Falcone hosted a “Ladies Night in Dentistry,” where she gave a lecture on prosthodontics.

UConn had several activities including multiple lectures, an interactive Lab Night, ads on campus TV monitors, and social media posts.

Massachusetts: Dr. Lisa Thoms spoke to the local Boys and Girls Club about oral health, and the Mayor officially proclaimed NPAW in the City of Waltham.

Harvard School of Dental Medicine held an Advanced Prosthodontic Forum, which included a lecture and an interactive planning workshop.

New Jersey: Dr. Stephen Hudis offered complimentary oral cancer screenings, published a Letter to the Editor, and had promotional signs.

Rutgers School of Dental Medicine advertised NPAW on their lobby TV monitors, had an informational table, and a prosthodontic presentation was given to the senior class.

Region 2

Florida: Dr. Derek Gatta filmed a segment on prosthodontics at his local NBC affiliate.

Georgia: The ACP Georgia Section and Augusta University hosted a pizza party for undergraduate dental students. Prosthodontic residents also provided a free set of complete dentures to a military veteran.

Maryland: University of Maryland prosthodontic residents and Dr. Carl Driscoll engaged predoctoral students with presentations.

North Carolina: Dr. Jonathan Hunter Dawson received an official proclamation from the City of Greensboro declaring NPAW.

Pennsylvania: Dr. Robert Bentz celebrated in several ways, notably delivering custom-made NPAW tomato pie pizzas to neighboring dental offices.

Penn Dental Medicine had activities throughout the week including lunch and learns, hands-on microscope sessions, and a lecture that was streamed online. The Prosthodontics Club also had a social media campaign using the hashtag #Pennpaw.

Dr. Elaine Torres-Melendez spoke several times on prosthodontics and made special NPAW shirts.



Army

MEMBERS FROM ALL 7 REGIONS PARTICIPATED

Region 3

Alabama: Dr. Cramin P. Wiltz hosted an open house and received an official proclamation from the Governor of Alabama declaring NPAW in the state.

Illinois: Mayor Rahm Emanuel declared NPAW in the City of Chicago, home of the ACP Central Office.

Kentucky: The Kentucky Section of the ACP hosted a Prosthodontics Study Club with 30 ACP members, residents, and students from Lexington and Louisville in attendance.


The University of Louisville hosted three separate discussions on complex cases and Dr. Loana Tovar Suinaga was featured in U of L's campus news.

Missouri: The Missouri Section held a meeting with ACP members from Missouri and Kansas attending.

Ohio: Prosthodontic residents at The Ohio State University held a lunch and learn which featured "Prosthodontic Jeopardy."



Manitoba



Nebraska



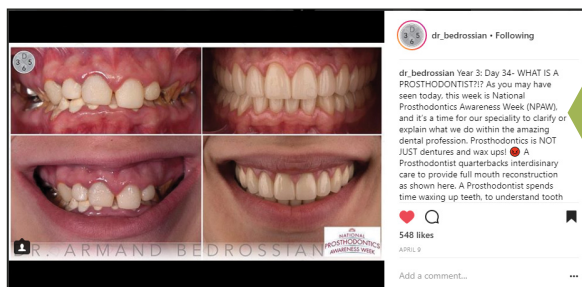Oregon

Region 4


Nebraska: Creighton University prosthodontic residents fabricated removable prostheses for five patients in an Omaha shelter.

Texas: Dr. Ernesto Carmona Jr. did free denture repairs for all patients who came in during NPAW.

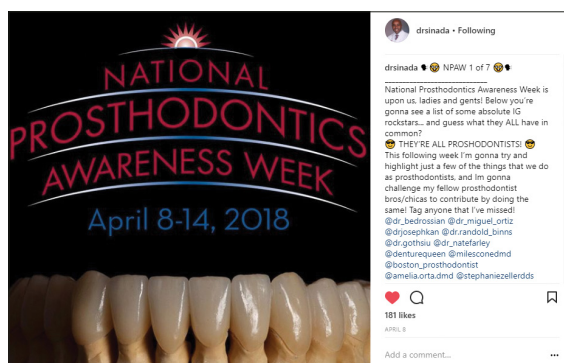Social Media: Dr. Naif Sinada posted on Instagram each day of NPAW highlighting complicated cases, and challenged his colleagues and almost 9k followers to also post during NPAW.



OVER **22,000 INTERACTIONS**
WITH NPAW POSTS ON SOCIAL MEDIA



Connecticut



Instagram

Region 5

California: Dr. Ronald Koslowski received an official proclamation from the California 27th Senate District declaring NPAW in the district.

Oregon: Students at Oregon Health & Science University participated in a denture setup competition where the winners got money and everyone got pizza!

Social Media: Dr. Armand Bedrossian posted several complicated cases on Instagram, highlighting the specialty to his 21.3k followers.

Dr. Stephanie Zeller posted a video showing a full-arch maxilla from start to finish to her 11k Instagram followers, garnering over 4k views.

Region 6 (Federal Services)

Army: Dr. Bryan McLaughlin, Chief of Prosthodontics at Fort Bliss, hosted a lunch and learn lecture to Army dentists and staff at Fort Bliss.

Region 7 (International)

Canada: Drs. Charlene Solomon and Igor Pesun celebrated at the University of Manitoba by displaying the NPAW logo on clinic monitors and participating in an Oral Cancer Awareness Initiative. ■



Pennsylvania



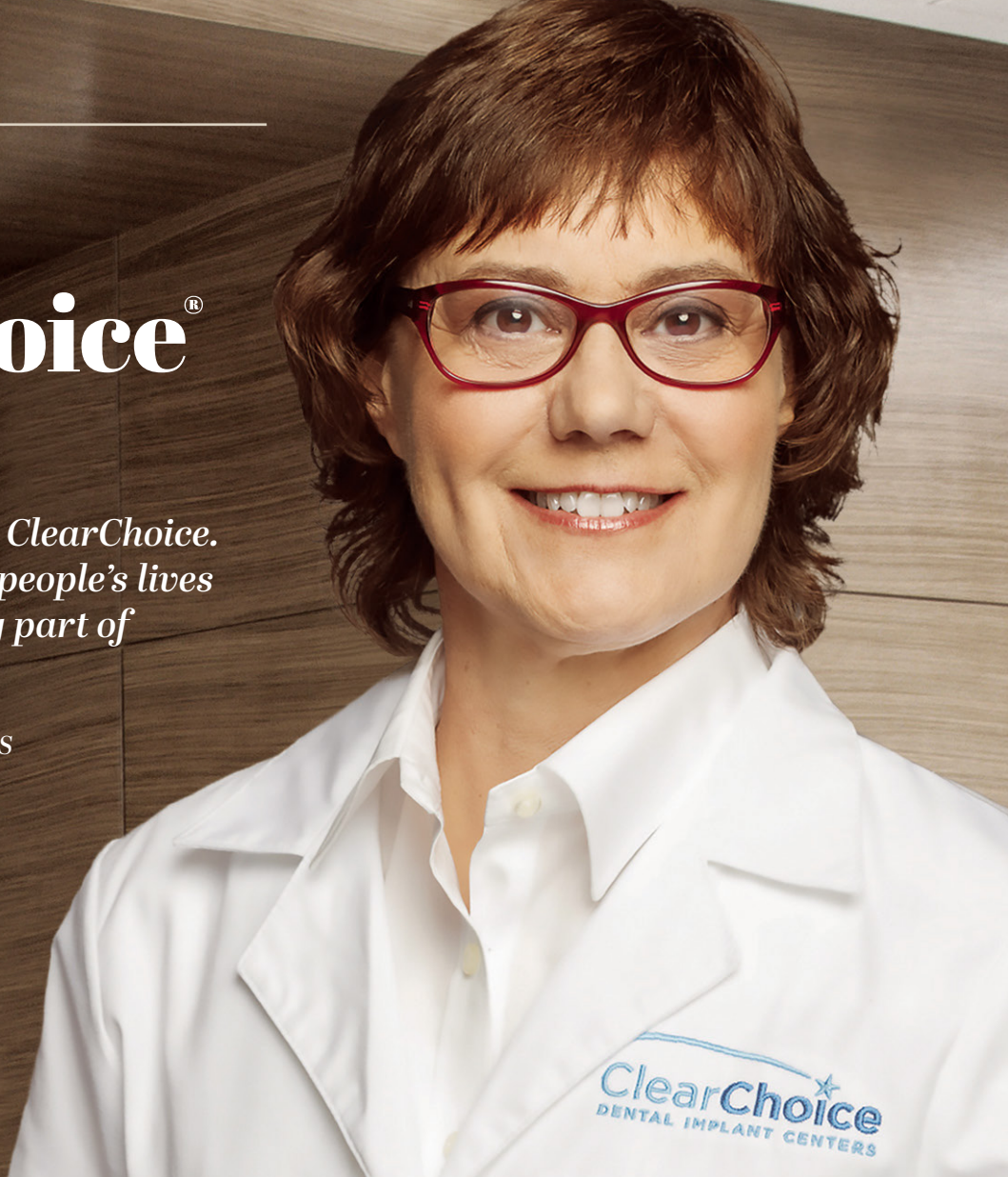Texas

CHANGE LIVES

With ClearChoice®

"I love the work I do at ClearChoice. To see the changes in people's lives is the most rewarding part of my practice."

— Dr. Rhonda F. Jacob, DDS, MS
Prosthodontist
Diplomate, American Board
of Prosthodontics




Why Practice at a ClearChoice Dental Implant Center?

- Innovative, Full-Service Implant Centers
- Quality Patient-Centered Care
- Over 55,000 patients served by the ClearChoice network
- Outstanding Compensation & Benefits
- Professional connections through a national network

Contact us today for opportunities nationwide.
www.doctorrecruiting.clearchoice.com
doctorrecruiting@clearchoice.com



Journal of Prosthodontics Appoints New Editor-in-Chief



Dr. David Felton
and Dr. Radi Masri

After leading the *Journal of Prosthodontics* through 15 years of growth and modernization, Dr. David Felton turned over the reins as Editor-in-Chief to Dr. Radi Masri on July 1.

When Dr. Felton took over as Editor-in-Chief, the *JoP* received about 60 manuscripts annually, but now receives over 600. That growth means that instead of a quarterly 65-page journal, ACP members now receive a 95-page journal nine times a year. Dr. Felton oversaw the shift to an all-online submission and review process, implemented an Editorial Review Board, and instituted annual virtual issues. Perhaps most importantly, he was instrumental in the *Journal of Prosthodontics* being indexed in *Journal Citation Reports* and granted an impact factor, which is a globally recognized measure of a journal's scientific quality.

Dr. Felton humbly recognizes the influence of the *JoP*'s two previous Editors-in-Chief, Dr. Ken Stewart and Dr. Patrick Lloyd, who were responsible for starting and maintaining a new journal. "It's easy to look good when you can stand on the shoulder of giants in the field," says Dr. Felton. "It has been an honor to serve as the third Editor-in-Chief of the *Journal of Prosthodontics*, as this has truly been one of the highlights of my academic career."

Dr. Felton feels lucky to hand the reins along to someone of the caliber of Dr. Radi Masri, saying, "Dr. Masri is incredibly talented, and will help move the journal to even greater heights."

Dr. Masri recognizes he has big shoes to fill, noting, "Dr. Felton's contributions to the journal are indicative of his astute management, sharp vision, and sensible judgment. He is a tough act to follow." According to Dr. Masri, the *JoP* now "occupies a healthy rank among indexed dental journals and is one of the leading prosthodontic journals." Thanks to the work of Dr. Felton to get the *JoP* to this position, Dr. Masri can now turn his focus to his primary and immediate goal: "to cement the status of the *JoP* as the premier journal for the specialty of prosthodontics."

By attracting the best prosthodontic research and expanding its authorship and reviewer pool, the *Journal* hopes to always represent the ACP and the specialty of prosthodontics as a premier source of science-based dental research.

ACP Executive Director Receives Reach Award from National Louis University



Dr. Linda Caradine-Poinsett received the Reach Award from National Louis University at the Reach Awards Gala on June 5, 2018. The event celebrates notable alumni who are making a significant impact in their fields.

The Reach Award is presented to an individual who exhibits exceptional character as well as a sense of higher purpose in life and work, thereby increasing opportunity and quality of life for others.

"For those of us who aspire to be in leadership, we must understand that leadership is about service to others," said Dr. Caradine-Poinsett. "We have an obligation to mentor and guide future leaders in our care. Therefore, we must not give up on our dreams because we never know what impact we will have on others."

Predoctoral and Postdoctoral Educators in Chicago



Over 100 educators representing more than 50 different institutions met in Chicago, April 13-14 to discuss current issues in prosthodontic education.

The spring conference is unique in that no other specialty brings together educators from predoctoral and advanced programs for a time of networking, community, education, and updates. This meeting has been crucial over the years in providing a platform to inform and discuss new CODA standards, OSCE, faculty calibration, Digital Dentistry Curriculum, and more.

This conference was funded by the ACPEF thanks to the support from Henry Schein, Ivoclar Vivadent, Nobel Biocare, and Straumann. The meeting will reconvene in Baltimore on Oct. 31 at the ACP Annual Session.

Upcoming Events

Prosthodontic Review Course

Sept. 7-8, 2018
Seattle
Prosthodontics.org

48th Annual Session

Oct. 31-Nov. 3, 2018
Baltimore
acp48.com

Digital Dentistry Symposium

Feb. 19-20, 2019
Chicago
Prosthodontics.org

National Prosthodontics Awareness Week

April 7-13, 2019
Prosthodontics.org/NPAW

THE EVOLUTION OF DIGITAL DENTISTRY / Total 6 CE Credits / 30 Seat Limit

Featuring the renowned

Markus B. Blatz, DMD, PhD

"Evolution of Digital Dentistry"

An Update on Ceramics, CAD/CAM, Bonding, and Implants

3 CE Credits



3shape

Albert Tambolleo, Regional Business Manager-East

"3Shape TRIOS, Growing Your Practice for a Simplified Digital Workflow"

Hands-on: 3Shape TRIOS Scanner

3 CE Credits



6 CE Credits Total	Early Bird ends 10/15	Full Price from 10/16
Dentist	\$420	\$520
Student	\$220	\$320

ADES

Academy of Dental Esthetics and Sciences

www.academyofdes.org

info@academyofdes.org / 781-388-0016

Exclusive One-Day Seminar in Boston

Friday, November 16, 2018

CUSP
DENTAL LABORATORY

ADES, The Educational Division of Cusp Dental

Sponsors:

3shape

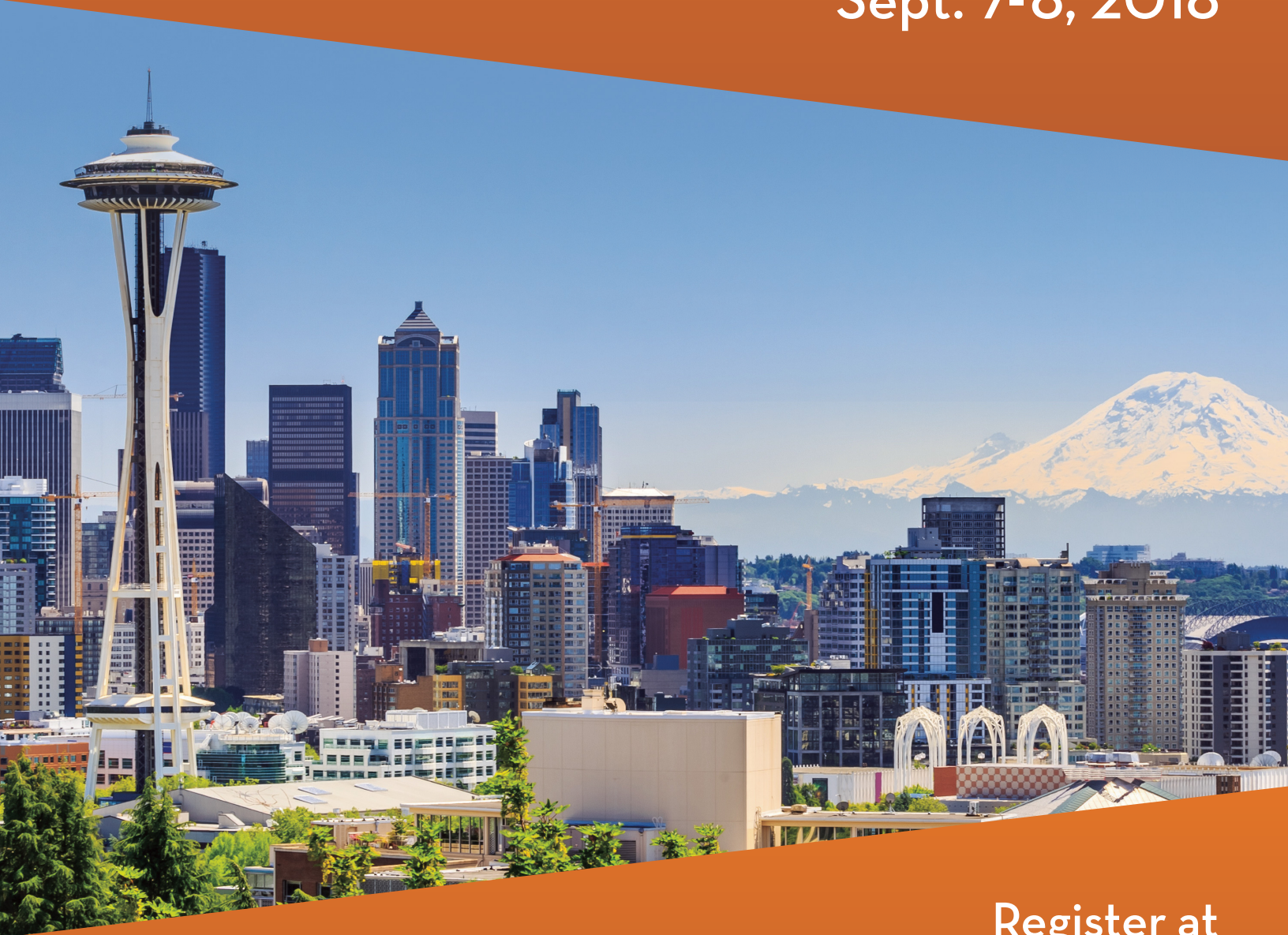kuraray Noritake

HENRY SCHEIN®

ASAHI REFINING

Prosthodontic Review Course

Seattle
Sept. 7-8, 2018



Register at
Prosthodontics.org

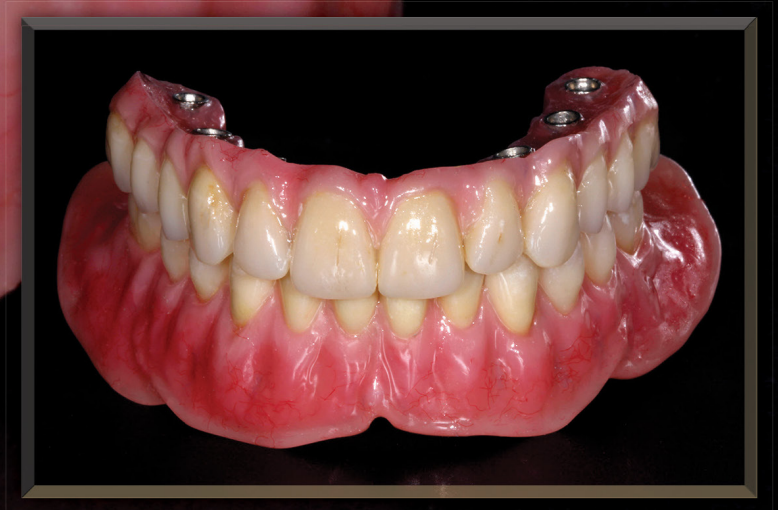
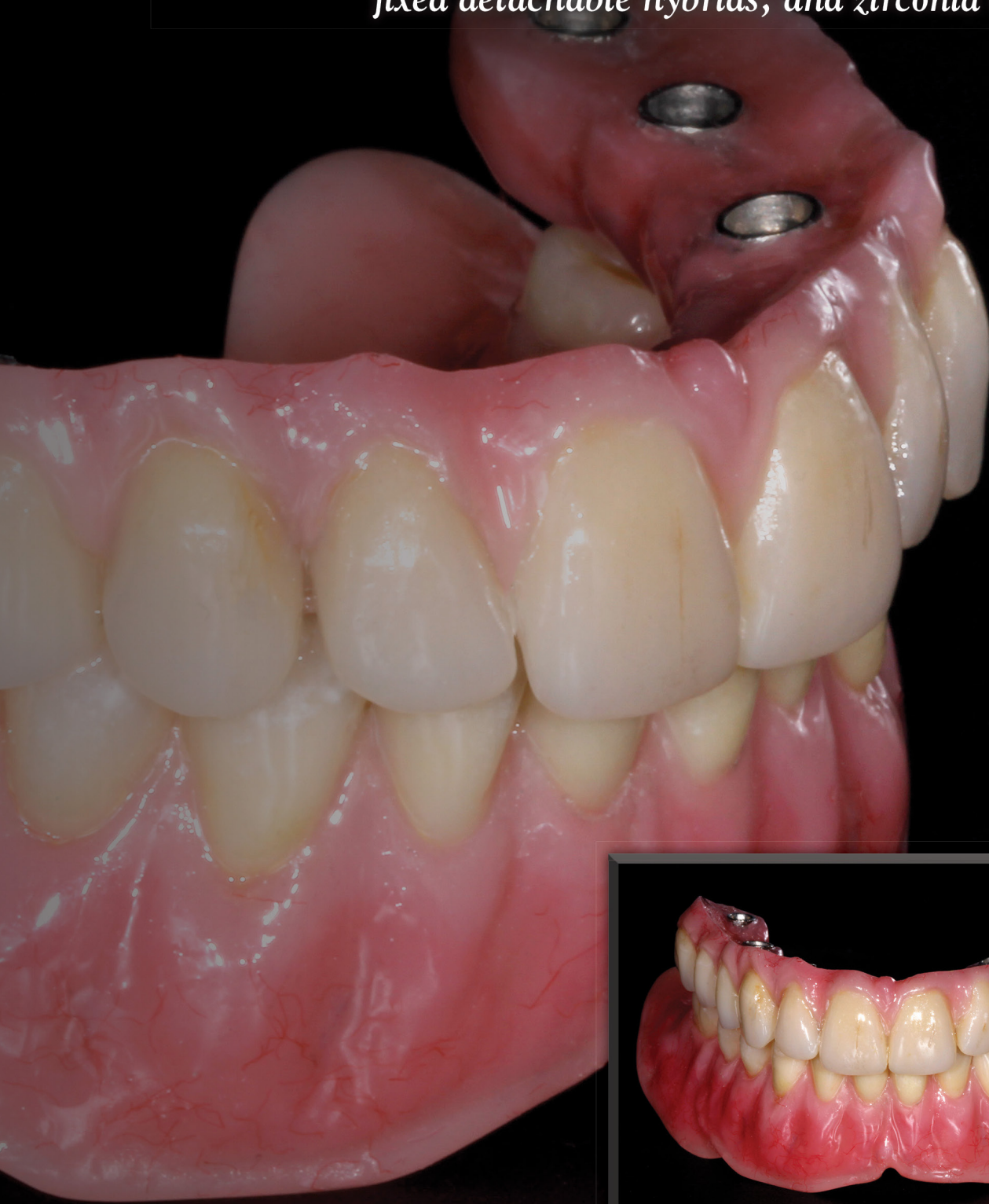
AMERICAN COLLEGE OF
PROTHODONTISTS
Your smile. Our specialty.®

Sponsored by:



Specializing in implant retained overdentures, bar-overdentures, fixed detachable hybrids, and zirconia restorations.



BVDL 

Bay View Dental Laboratory

757.583.1787 || WWW.BVDL.COM

Welcome New Members

April – June 2018

Reinstated Dental Technician

Alliance Affiliate

Dr. David E. Shrum

Reinstated Members

Dr. Piriya Boonsiriphant

Dr. Rainier A. Urdaneta

Dr. Jedediah W. Wooldridge

New International Member

Dr. Ysidora Torrealba

Reinstated International Member

Dr. Diego M. Ardenghi

New Predoctoral Alliance Affiliates

Ms. Carlie Lynne Amore

Mr. Robert J. Ault

Mr. Laten E. Barham

Ms. Joanna L. Boutwell

Ms. Jaclyn M. Danko

Ms. Lacey E. Galliano

Mr. Kevin Hadar

Mr. Anthony Hicu M. Nguyen

Ms. Gabrielle Nguyen

Mr. David Schwartz

Ms. Ann-Marie Simon

Mr. Jacob Roger Smith

Ms. Katherine Tran

Mr. Brandon J. Walker

Mr. David A. Cruz Walma

New Resident/Graduate Student Members

Dr. Zainab J. Ajeeb

Dr. Ahmad M. Alawadi

Dr. Amira F. Alhameed

Dr. Maryam M. Al Rasheedi

Dr. Waleed Alsaeid

Dr. Arthur J. Bigsby, III

Dr. Jamie E. Bruno

Dr. Ashley C. Budasoff

Dr. Weon Jae Choi

Dr. Valentina Coelho

Dr. Breanne C. Dufault

Dr. Asil Mah'd Ellauzi

Dr. Dianne M. Gan

Dr. Morgan A. Gwin

Dr. Fatemah B. Ibrahim

Dr. Charmaine Ip

Dr. Samuel R. Lee

Dr. Venkata Mohan K. Mutnuri

Dr. Quoc Thong Nguyen

Dr. Anne K. Press

Dr. Marianna Nicolette Rokkas

Dr. Nikita Sinha

Dr. Shivani C. Suvarna

Dr. Kinjal Vora

Reinstated Resident/Graduate Student Member

Dr. Samuel I. Richards

Job Opportunities

Arkansas (Fayetteville) – Seeking a Prosthodontist to Join Our Thriving Practice: Ozark Prosthodontics, located in beautiful NW Arkansas, has an immediate opening due, thankfully, to significant growth in patient treatment. We are a surgical and restorative practice that uses digital technology in both our clinic and lab areas. We understand, and are very successfully using medical insurance to help patients receive very necessary treatment, by reducing their out of pocket expenses. Our on-site laboratory is managed by Luke Hasegawa, CDT, Oral Design Member. Our newly renovated 5600 sq ft facility opens Summer 2018 and will be truly state of the art. If you are sincerely interested in learning more about us, please contact our COO, Sean Pitman at spitman@ozarkpros.com, experiencefayetteville.com, northwestarkansas.org, crystalbridges.org

California (Santa Clarita Valley) – Associateship leading to partnership and buy out. Modern digital 40 year old prosthodontics practice, seeking associate to become partner and eventually owner. Located in the Santa Clarita Valley, in house lab, own space, long term staff currently referring out all implant placement. Excellent opportunity for motivated, personable prosthodontist. Contact xbaumgartner@me.com.

Colorado (Fort Collins) – Additional prosthodontist needed for a busy practice: Established private practice in Fort Collins is seeking an additional provider to work with our great team and awesome patients! Current Colorado licensure is required as we are seeking to fill this position soon. Experience with AO4 is needed and salary is negotiable along with buy-in opportunities. Interested candidates can email their CV to rbergloff@hotmail.com or call at 720-431-6060.

Delaware (Wilmington) – Christiana Care Health System is seeking an experienced community or academic Prosthodontist with a strong background in restorative dentistry, including implant prosthodontics. The candidate should also have experience in hospital dentistry, including exposure to treating patients in the OR. The candidate should have experience teaching on the graduate level and should be able to continue the development of the didactic and clinical programs, particularly in the areas of restorative dentistry and implant prosthodontics. Part-time and full-time interest will be considered.

ACPEF Research Fellowships: Call for Applications

The ACP Education Foundation is committed to assisting the dental profession in its quest for continuous improvement in clinical care. Each fall, the ACPEF awards research fellowship grants in the amount of \$6,000. These are awarded to support meritorious research proposals that seek to advance basic scientific and applied clinical knowledge in the area of prosthodontics. Any investigation relevant to prosthodontic care is appropriate. This includes fixed, implant, maxillofacial, and removable prosthetics. Individuals are eligible if they are currently enrolled in a postdoctoral prosthodontic program accredited by the Commission on Dental Accreditation of the American Dental Association and are a Resident/Graduate Student Member, in good standing, of the American College of Prosthodontists.

Applications are due by Aug. 31. Submission guidelines are available online at <https://www.prosthodontics.org/acp-education-foundation/grants-awards/>

ACPEF Research Fellowships are supported in part by an unrestricted educational grant from Procter & Gamble Company.

Visit website to apply: http://careers.christianacare.org/jobs/Faculty_Position_-_Prosthodontist_or_Dentist/Wilmington_Delaware/105/138294/

Georgia (Gwinnett and Buckhead) –

A well established and growing modern Prosthodontic practice is offering an Associateship opportunity leading to Partnership to the right candidate. Join our amazing team in a fully digital environment: paperless, CBCT, Trios IOS, bench top scanners and fully equipped in-house laboratory. Quality, outcome and patient care are our priorities. FFS/PPO only. Competitive salary with benefits. Please email CV to info@implantoption.com.

Illinois (Skokie) – Outstanding partnership opportunity for a talented, caring, energetic, detailed-oriented Prosthodontist with excellent verbal and interpersonal skills. Beautiful office with exceptional laboratory support. Fee for service practice with emphasis in Fixed Prosthodontics, Implants and Restorative. Send CV to: oralrehab1@gmail.com. Website: drcpia.com.

Illinois (University of Illinois at Chicago) – FACULTY OPEN RANK (TENURE/ NON-TENURE TRACK)-ADVANCED PROSTHODONTIC SCIENCES

Department of Restorative Dentistry, College of Dentistry, University of Illinois at Chicago

The Department of Restorative Dentistry at the University of Illinois at Chicago is seeking qualified candidates for full time open rank faculty positions in either the tenure or non-tenure clinical track for the Advanced Prosthodontic Sciences program. This is a special opportunity to join a well-established and recognized team of individuals and program. The Department seeks individuals with a strong commitment to interdisciplinary care and willingness to engage with all departments in the College.

Responsibilities are focused on the Advanced Prosthodontics Educational Program including all aspects of preclinical, didactic, clinical, implant and digital prosthodontics. Predoctoral teaching related to Prosthodontics may also be part of the responsibilities. Qualifications include a DDS/DMD degree, successful completion of a CODA accredited advanced education program in Prosthodontics, American Board of Prosthodontics Specialty Eligibility or Certification, and prior teaching experience. Candidates with training and/or documented experience in research will be preferred. Candidates must be eligible for licensure in

Illinois. For the tenure position additional qualifications are documented publication record, Board certified or board eligible (if board –eligible, the candidate will be expected to complete the certification process within three years of the date of hire), previous university-level teaching experience, strong commitment to research, successful record of obtaining external grant funding, leadership experience in an academic environment. Salary, academic rank and tenure/non-tenured track will be commensurate with experience and qualifications within the norms and criteria for faculty appointments in the Department of Restorative Dentistry.

For fullest consideration applicants should include a cover letter, C.V. and names of three references by June 8, 2018 at: <https://jobs.uic.edu/job-board/job-details?jobID=94789> (tenure position) or <https://jobs.uic.edu/job-board/job-details?jobID=94134> (non-tenure position). The positions will begin after July 1, 2018. Positions to remain open until filled.

The University of Illinois at Chicago is an Equal Opportunity, Affirmative Action employer. Minorities, women, veterans and individuals with disabilities are encouraged to apply. The University of Illinois may conduct background checks on all job candidates upon acceptance of a contingent offer. Background checks will be performed in compliance with the Fair Credit Reporting Act.

Illinois (University of Illinois at Chicago) – FACULTY OPEN RANK-(TENURE/ NON-TENURE TRACK)

Pre-Doctoral Dental Education, Department of Restorative Dentistry, University of Illinois at Chicago

The Department of Restorative Dentistry at the University of Illinois at Chicago is seeking qualified candidates for full time open rank faculty positions in either the tenure or non-tenure clinical track for the Pre-Doctoral education program. This is a special opportunity to join a well-established and recognized team. The Department seeks individuals with a strong commitment to interdisciplinary care and willingness to engage with all departments in the College. Responsibilities will include preclinical and clinical instruction in all aspects of the Restorative Sciences.

Qualifications include a DDS/DMD degree and prior teaching experience. Candidates must be eligible for licensure in Illinois. Candidates with training and/or documented experience in research will be preferred. For the tenure position, additional qualifications include a Master of Science Graduate Degree or PhD, postdoctoral training in a

clinical science (e.g. Operative Dentistry, Prosthodontics, Restorative Dentistry), experience in clinical teaching and mentoring, strong commitment to research and documented research experience, successful record of obtaining external grant funding, documented history of publication. Salary, academic rank and tenure/non-tenured track will be commensurate with experience and qualifications within the norms and criteria for faculty appointments in the Department of Restorative Dentistry.

For fullest consideration applicants should include a cover letter, C.V. and names of three references by June 8, 2018 at: <https://jobs.uic.edu/job-board/job-details?jobID=94790&job=faculty-open-rank-tenure-tenure-track-restorative-dentistry> (tenure position) or <https://jobs.uic.edu/job-board/job-details?jobID=94133&job=faculty-open-rank-non-tenure-restorative-dentistry> (non-tenure position). The positions will begin after July 1, 2018. Positions to remain open until filled.

The University of Illinois at Chicago is an Equal Opportunity, Affirmative Action employer. Minorities, women, veterans and individuals with disabilities are encouraged to apply. The University of Illinois may conduct background checks on all job candidates upon acceptance of a contingent offer. Background checks will be performed in compliance with the Fair Credit Reporting Act.

Maine (Portland) – Established

Comprehensive Prosthodontic Practice Seeking Associate: A terrific opportunity exists for an experienced outgoing prosthodontist associate to join an established comprehensive practice offering aesthetic, fixed, implant and removable prosthodontics as well as comprehensive dental care. Associateship with a view toward partnership. Located in a newly expanded office in Portland, Maine. In-house lab on site. Please e-mail resume / C. V. and photos of work to info@prosthodonticsassociates.com.

Maryland (Baltimore County) – Seeking F/T Prosthodontist Associate Interested in Future Ownership: Established, thriving Prosthodontic Practice in Baltimore County, Maryland seeking outgoing, personable Prosthodontist Associate leading to partnership and ownership. We are a busy, one provider, fee-for-service practice. We educate our patients in the Healthy Mouth/Health Body Connection while providing cosmetic, implant and reconstructive dentistry. We have a great Team that is there to support our patients, doctor and future associate!

We are digitally connected with CBCT, Trios scanner and four of six operatories have surgical operating microscopes. Please send CV, case photos and brief description of your expectations for this job opportunity. Email information to admin@drboenning.com.

New York (Manhattan) – Associate to Partner Position. Unique opportunity. Midtown Manhattan Prosthodontic Practice with full service on-site lab and academic affiliation, offers associate to partner opportunity. Implant dentistry, prosthodontic training from an accredited ADA training program required. 2-5 years' private practice experience welcomed. Please contact Yana Spivak at (212)750-0050

New York (Manorville) – Incredible Opportunity for Prosthodontist at Ultra modern implant oriented practice with experienced implant surgeons. Amazing and incredible opportunity in a brand new dental office located in Eastern Suffolk County. Practice boasts 200 new patients a month. Completely state of the art, 8 operatories, all digital, \$5M+ production. Contact cgiangreco@puredentalimplants.com.

New York (Syracuse) – Syracuse Prosthodontic and Implant Practice Leading to Ownership: Thriving 33-year-old Prosthodontic practice looking for qualified candidate to buy in 6 months to 1 year. Gross revenues are over \$1.2 million on 30 hours per week with low overhead. 2000 sq/ft office located in medical and hospital district with 4 fully equipped ops, all digital including new Sirona Galileos 3D, T-scan, TruDenta Diagnostics, latest CEREC Acquisition unit and MCXL Milling unit, Piezosurgery, fully computerized office. Good size fully equipped laboratory. Placing 70 implants per year. Central New York has the beautiful Finger Lakes with the opportunity to live on the water and commute to work easily. We are surrounded by wineries, great hospitals with easy access to medical care, several major universities, medical school, VA hospital, and a vibrant downtown. The university has competitive Division I sports programs. It is a great place to raise a family with affordable housing and good schools. Please send resume and cover letter to jbsprosthodont@gmail.com. Call 315-447-3145

Oregon (Portland) – Seeking an Associate Prosthodontist to Join Our Multi-Disciplinary Practice. Fusion Dental Specialists is located in diverse, beautiful, and friendly Portland, Oregon. We have a

growing practice that offers full Prosthodontic and Periodontic services with state of the art equipment. This is a full time opportunity with guaranteed patients and support staff to start. Ambitious individuals wanting to drive growth are encouraged to respond. We have a great team ready to welcome a new specialist. Please email resume to admin@fusiondentalspecialists.com.

Pennsylvania (Lancaster) – Seeking Part Time Prosthodontist / Maxillofacial experience: The Lancaster Cleft Palate Clinic is offering a unique opportunity to treat patients with facial clefts, head and neck cancer, and other craniofacial conditions. The clinic is home to the first cleft and craniofacial team in the United States and runs a multi-specialty medical and dental practice. The position is part time, but full time work may be arranged. An academic appointment, hospital privileges and loan repayment may be available for the interested candidate. Interested candidates may email Lprada@cleftclinic.org.

Pennsylvania (Villanova / Philadelphia Main Line) – Prosthodontic/Esthetic Dentistry Practice seeking a Prosthodontist for our team. Well established, adult only, fee for service practice in custom renovated, historical building with high visibility. Implant surgical suite, onsite dental laboratory, staff orthodontist. Prestigious Villanova (Philadelphia Main Line) location. Please send CV, photos of cases, letter of intent to jrgdmd@gmail.com. Those interested in future ownership only. createbeautifulmiles.com

Texas (Dallas) – Seeking BOTH Surgical & Restorative Prosthodontists
Description: Perform all phases of implant prosthetic dentistry; Will have leadership role in the center with an emphasis on increasing center profitability; Possess a patient-centered mindset and approach to treatment planning and daily center operations.; Consult with new patients; Possess excellent social skills
Requirements: Professional Degree: DDS/ DMD; Certificate in Prosthodontics from an ADA accredited program; Licensed in Texas; IV Sedation License preferred (willing to pay to obtain); Salary and Benefits: Competitive salary and bonus based on production. Email dra@fastnewsmile.com

Texas (Dallas-Ft. Worth) – Seeking Associate/ Partner: Solo Private Practice seeks ambitious, strong work ethic, high quality oriented Prosthodontist-Associate leading to Partnership. Low volume/ high production practice (\$2 million/year). Must have U.S.

DDS or DMD degree. Great opportunity in one of the strongest economies in the country. dentalimplantcenter.com. Email: david_mcfadden_dmd@yahoo.com

Virginia (Richmond) – SEEKING F/T PROSTHODONTIST in Richmond Virginia Area: RARE OPPORTUNITY LEADING TO PARTNERSHIP at top family dental practice! Outstanding productivity in 900k range, strong referral base. Current prosthodontist will introduce you to area dentists, referral specialists and patients under active care. Practice located in Chesterfield County, a thriving, affluent community located in Richmond area; top ranked schools. Send resume to info@lbdtransitions.com.

GUNDERSEN HEALTH SYSTEM.

Wisconsin (La Crosse) – Gundersen Health System based in La Crosse, WI is recruiting for a Prosthodontist to join the Department of Dental Specialties. This strong clinical practice encompasses the full scope of prosthodontics and maxillofacial prosthetics. You will have the opportunity to collaborate within a large, fully integrated system that is academically affiliated with the UW Madison. Proficiency in fixed, removable and implant prosthodontics and experience in maxillofacial prosthetics is desired. DDS/DMD degree with completion of an ADA accredited advanced education program in prosthodontics is required.

Gundersen Health System is a physician-led, non-profit, multi-specialty healthcare system that serves a multi-state region of WI, IA and MN. We employ over 650 medical staff and nearly 8000 total employees in our integrated system. Jon Nevala, jonnevala@gundersenhealth.org, 608-775-4224, gundersenhealth.org

Practices for Sale

Arizona (Phoenix/West Valley) – Established thirty-four year old prosthodontic specialty practice for sale in Phoenix, Arizona. Full spectrum of prosthodontic services offered. Implant based care a major portion of patient treatment including surgical placement and adjunctive grafting and enhancement procedures. One million plus collections for over sixteen years. Fee for service, no HMO, PPOs or insurance contracts. Dentrix office management, digital radiography, and 3Shape lab scanner. Owner will remain per request of new doctor in transition and/or mentor surgical skills for implant based procedures. Enjoy year

round outdoor activities in one of the fastest growing cities in the United States. Contact Fred Heppner, fredh@arizonatransitions.com, #480-513-0462.

California (Escondido) – Prosthodontic practice in Escondido, CA (North San Diego County). Successful fee for service Practice over 50 years, with current prosthodontist owner since 1999. 4 fully equipped operatories in 2200 sq. ft, beautifully designed environment in a standalone building, with ample parking and room for expansion. Call 760-443-3603

California (San Francisco Bay Area) - Out-of-network with insurance industry. Located in affluent suburb adjacent to Bay Area's premier retirement community. 2017 billed \$1.21 Million, collected \$1.18 Million. Doctor took 7-weeks off. 4-days/week of Hygiene booked 6-months in advance, Doctor booked 3-months. Beautifully designed suite has "town & country" feel in peaceful garden setting. Paperless charting. Doctor shall provide whatever transition assistance is requested. Stellar opportunity! For additional information, contact Ray Irving at 415-899-8580 or Ray@PPSsellsDDS.com. For full particulars, go to PPSsellsDDS.com.

Idaho (Northern Idaho) – Well located prosthodontic practice available for walk away sale. Solid base of loyal hygiene patients & referrals. 6 ops-digital; Dr. refers out implant placement. Lots of opportunity to grow. Owner is working a relaxed schedule and ready to retire. Contact Wendy Hirai, Consani Associates, at (208) 870-8623 or email wendy@mydentalbroker.com.

Illinois (Chicago Suburbs) – Chicago Suburbs - Prosthodontic / General Practice for Sale: Busy prosthodontic office with a strong general dentistry component for sale by owner. Practice is located in the downtown area of a near Chicago suburb. Owner is relocating to another state for personal reasons. All fee-for-service. Gross revenues have consistently been around \$825,000 over the past three years. Refers out endodontics and orthodontics. Owner practices with a conservative philosophy. Contact ChicagoProsthSale@gmail.com for more information.

Michigan (Southeast Michigan) – SE Michigan Established Prosthodontic Practice with flexible transition plan looking toward retirement. The practice offers steady revenue of 1.6mm with excellent cash flow, 100% fee for service, well established hygiene program, fully trained staff and doctor ready to transition ownership. After tax cash flow and practice proforma available after NDA in place. Please send confidential response to: michigandentist2017@gmail.com.

Minnesota (Duluth) – Highly successful, well-established prosthodontic practice in Duluth, Minnesota seeking a board eligible or board certified Prosthodontist to take over thriving practice. Practice is totally fee for service with average of mid \$900,000s in collections annually on 3 1/2 days/week. Practice is heavily oriented in implant solutions, but all aspects of prosthodontics are offered. Practice is located in a beautiful, well maintained suite in the Duluth Medical Arts Building. Office has 2 ops (with an option for a 3rd) with I-CAT CBCT, iTero Element intraoral scanner, and a state of the art removable/fixed laboratory. Will stay on as long as necessary for a smooth transition. Duluth was labeled as the "Best Outdoor Town" by Outside Magazine in 2014. Contact: Dr. Doug Erickson at dne@drdougerrickson.com. 218-722-8118 (work). 218-343-3983 (cell) drdougerrickson.com

New Mexico (Albuquerque) – Prosthodontic Practice for sale in beautiful Albuquerque - great location in southwest. Owner retiring. Three and a half day week. Great growth potential. Fee-for-service, no insurance. Motivated seller. Flexible transition. Contact Andy Eberhardt - aeberhardt@dentalcooperative.com.

Pennsylvania (Northeastern Pennsylvania) – Outstanding opportunity to acquire a thriving surgical/prosthodontics practice and surgery center located in beautiful Northeastern Pennsylvania. This is a perfect opportunity for a prosthodontist who has surgical training in implant dentistry, extractions, grafting procedures, etc. Owner is offering a turnkey operation with the possibility of owner financing. This is the ideal setting for someone who wishes to settle down affordably and build their own practice in an area within 2 hours of NYC and Philadelphia. We are in the process of constructing a new building which will house our dental practice. This central

location, which encompasses both aspects of this organization, gives the patients the convenience of receiving top care in one location. We are very excited about our new office/facility and are looking for a prosthodontist to share this lucrative opportunity. Contact: Prosthodontist.pa@gmail.com

Virginia (Central Virginia) – Perfect opportunity to be a part of a successful prosthodontics practice, ideal long term transition plan. Work alongside a master at his craft. Above average fee parity, fee for service, 1 million plus producing business make this the ideal scenario for a young highly skilled professional. Please go to commonwealthtransitions.com and register as a buyer for free to find out more details.

Washington (Seattle) – Fee for Service Cosmetic/Reconstructive Practice for Sale in Greater Seattle Area: Well-established practice over 20 years same location. 2016-17 Collections avg over \$1.4M/yr. Includes full time hygienist. Well anointed and modern 2,000sf office, 4 fully equipped and generous operatories. Fully Digital chartless practice including Dentrrix/Dexis/Pan/CBCT. Part time Periodontist willing to stay for implants/surgery. Well trained and experienced staff will continue and assist w/ transition. Selling doctor will mentor/assist buyer for a limited time to ensure a smooth transition. Contact: Buck Reasor, DMD, Reasor Professional Dental Services, info@reasorprofessionaldental.net 503-680-4366

Services Available

Private Implant Mentoring



OFFERED BY: Dr. Thomas Balshi
Offering Private Mentoring at your office. Designed to help prosthodontists with implant planning, surgery, immediate loading and patient management in the privacy of the prosthodontists private office, focused predominantly on the East coast. For more information on pricing and to contact me, visit privateimplantmentoring.com or contact Dr. Thomas Balshi at (215) 872-7677 or tjbalsi@aol.com.

2018 FALL WORKSHOPS

Ueli Grunder, DMD

Esthetics in Implantology

November 29–30, 2018



Arndt Happe, DDS, Dr med dent

Vincent Fehmer, MDT



Implants in the Esthetic Zone:
The Art and Science
December 3–4, 2018

REGISTER NOW

www.quintpub.com/grunder | www.quintpub.com/happe

FORTHCOMING

Giovanni Zucchelli — March 2019

Joseph Kan — April 2019

Otto Zuhr — May 2019

Tomas Linkevičius — Fall 2019

Cleopatra Nacopoulos — Fall 2019

IPS e.max® ZirCAD®

▶▶▶ A natural gradient of chroma and translucency

Strength & Durability

ZIRCONIA never looked so good!

**MAKE IT
e.max
ZIRCONIA**

Introducing IPS e.max® ZirCAD® Multi

- **High strength:** Up to 30% higher flexural strength and 50% higher fracture toughness compared to common translucent zirconia materials (5Y-TZP).
- **Conservative preparations:** Only 0.8 mm tooth reduction in the anterior and 1.0 mm tooth reduction in the posterior is required.
- **High productivity:** Chair-time saving cementation options include conventional and self-adhesive cementation.

For Esthetics, Performance and Reliability, Make it e.max.
Visit makeitemax.com to learn more.

ivoclarvivadent.com
EXPLORE SHOP LEARN

For more information, call us at 1-800-533-6825 in the U.S., 1-800-263-8182 in Canada.
© 2018 Ivoclar Vivadent, Inc. Ivoclar Vivadent, IPS e.max and ZirCAD are registered trademarks of Ivoclar Vivadent, Inc.

**ivoclar
vivadent®**
passion vision innovation